

WABIP Newsletter



Volume 04

Issue 02

June 2016

Inside This Issue

Opinion/Editorial, 2

Technology Corner, 2,3,4

Tips from the Experts, 5,6

Humanitarian News, 7,8

Education and Training, 9,10

BOR News, 11

Research, 12,13

Upcoming Events, 14

WABIP Academy Webcasts, 15

Links, 15



EXECUTIVE BOARD

Zsolt Papai MD

Székesfehérvár, Hungary
Chair

Silvia Quadrelli MD

Buenos Aires, Argentina
Vice-chair

Hideo Saka MD

Nagoya, Japan
Secretary General

Hojoong Kim MD

Seoul, Korea
Treasurer

Eric Edell MD

Rochester MN, USA
President WCBIP 2018

Quangfa Wang MD

Beijing, China
President WCBIP 2020

Henri Colt MD

Laguna Beach, CA
Immediate Past-chair

STAFF

Michael Mendoza

General Manager

Judy McConnell

Administrator

Kazuhiro Yasufuku

Newsletter Editor-in-chief

Opinion/Editorial

It was wonderful to see many of my WABIP colleagues, new and longstanding, in Florence, Italy for the 19th WCBIP/WCBE World Congress. This innovative meeting not only offered the latest information about technology, education and research, but also provided hands-on workshops to allow for training on new as well as conventional interventional procedures.

1,300 participants from over 50 countries had access to keynote lectures, interactive sessions, and expert panel discussions that focused

on clinical as well as novel scientific discoveries. A record number of scientific abstracts (400 abstracts from 50 countries) and video award entries (26 videos submitted for participation in the WCBIP/WCBE Video Festival) were submitted this year which allowed for an outstanding program for attendees.

The Board of Regents meeting was very successful with 40 out of 57 members in attendance. Notable events was election of a new Vice-Chair (Dr. Silvia Quadrelli of Argenti-

na), and selection of Marseille, France to host the 2022 World Congress (Prof. Philippe Astoul as WCBIP President).

Apart from the conference itself, Florence offered a beautiful canvas and cultural experience for our members and time to catch up on old friendships, as well as meet colleagues new to the WABIP.

Thank you,

Dr. Kazuhiro Yasufuku
Editor-in-Chief



WABIP Board of Regents  Florence 2016

Technology Corner

Technology corner: Bronchoscopic Photodynamic Therapy with Photofrin for Malignant Central Airway Obstruction

Introduction: In patients with inoperable malignant central airway obstruction (CAO), photodynamic therapy (PDT) has been applied bronchoscopically to assist with tumor debulking and restore airway patency. PDT is a treatment that uses a photosensitizing agent (e.g. photofrin) and a particular type of laser light. The mechanisms of PDT laser light-tissue interactions after photofrin injection are complex, but in general, when photosensitizers retained in tissues are exposed to a specific wavelength of light, they produce a form of singlet oxygen that kills nearby cells. PDT uses a non-thermal laser to achieve these effects, but like with any laser, PDT-induced tissue interaction is affected by power setting and duration of exposure, but also by tissue oxygenation and vascular supply. Knowledge of basic PDT physics is warranted to assure desired effect and patient safety. This section will discuss the physics principles, indications and contraindications of PDT in malignant CAO.

Background: PDT has a unique mechanism of action when compared with laser or other ablative treatments. PDT with photofrin is a two-stage process; first, is the intravenous injection of photofrin at 2 mg/kg, administered as a single slow intravenous injection over 3 to 5 minutes on day 1; the second stage is laser light application on day 3.

This time interval of 40 to 50 hours should elapse between administration of photofrin and laser light application to allow relatively selective retention of photofrin within the tumor and clearance from other tissues. The red light activates photofrin to an excited state; the energy transfer causes reactive singlet oxygen and tumor cell death. In addition, excited photofrin causes vasoconstriction and vascular occlusion, which enhances tumor cell death. The end result is lysis and ischemic necrosis of cancer cells. Furthermore, PDT-induced systemic effects through immunologic changes have been described in the published literature. PDT can be applied via flexible or rigid bronchoscopy, depending on the indications and operator's experience or preference. The PDT diffuser fiber produces a 360-degree dissemination of light with a tissue penetration depth of 4-6 mm. This is likely shallower than with Nd: YAG 1064 nm (up to 1 cm), but deeper than what is achieved with Argon laser 514 nm (0.3 mm), KTP laser 532 nm (0.4 mm), Diode laser 805 (1.3 mm), APC at 30-90 Watts (1-3 mm) or cryotherapy (1-4 mm) (1). The photosensitizer is preferentially retained in the malignant cells, which allows treatment of diffuse visible and nonvisible disease once light application occurs. The 630 nm Diomed non-thermal laser thus allow relatively selective necrosis of target lesion up to 6 mm depth. The non-thermal laser is compatible with any of FiO₂ level, which is not the case for thermal ablative techniques. PDT endobronchial dosimetry for photofrin is based on specific indications. The total power output is predetermined by length of fiber diffuser but the standard power or time may be altered to result in a different treatment effect (i.e. increased or decreased depth of tumor necrosis). In general, for endobronchial cancers, a laser light dose of 200 J/cm of fiber optic diffuser length is applied 40–50 hours following injection with photofrin; this can be repeated, if needed, after debridement of residual tumor 96-120 hours after initial injection. The Diomed 630nm PDT laser software requires the user to input fiber length and dosimetry is automatically calculated.

Clinical applications: Bronchoscopic PDT is approved for the treatment of microinvasive endobronchial non-small-cell lung cancer (NSCLC) in patients for whom surgery and radiotherapy are not indicated and to reduce the degree of obstruction and palliation of symptoms in patients with completely or partially obstructing endobronchial NSCLC (2). PDT has been used for debulking a variety of other benign and malignant disorders but the majority of data is for malignant CAO from NSCLC. It has also been used as a neo-adjuvant therapy to reduce the extent of surgical resection or even convert originally inoperable patients to surgical candidates (3). Investigators have used it for symptomatic management of Stage I and II NSCLC (3, 4), or as part of multimodality therapy in the treatment of locally advanced disease (5), but most studies evaluated its role in palliation of malignant CAO. The goals of bronchoscopic PDT in this circumstance are to reduce endobronchial luminal obstruction, improve performance status and respiratory function and even improve hemoptysis and post obstructive pneumonia (6). Fiber type (flexible or rigid), length and positioning (adjacent or interstitial) depend on the tumor's vertical extent, location, pattern (mucosal vs. exophytic endoluminal) as well as desired depth of tissue effects. In a landmark prospective randomized study with a follow up period of 2 years, 31 inoperable patients with NSCLC and CAO were subject to either bronchoscopic PDT or Nd: YAG treatment (7). Patients were included if more than 4 weeks have passed from their last chemotherapy and more than 3 weeks from last radiation session. All had symptomatic complete or partial airway obstruction. Control bronchoscopy after either PDT or Nd: YAG laser resection was performed 1 week after PDT, every month for 3 months and at 6 and 12 months (and at 18 months, if possible) thereafter. Survival was significantly longer in the PDT group than in the Nd: YAG laser resection group (265 versus 95 days, $p=0.007$). In regards to the multimodal approach, one study aimed at assessing the safety and effectiveness of combined brachytherapy and PDT in patients with bulky endobronchial lung cancer (5). Thirty-two patients were treated with PDT followed by brachytherapy six weeks later; 24(75%) patients achieved complete response after initial PDT and 31/32 (97%) a complete histological response with combined treatment. In fact, 26 (81%) patients were free of residual tumor and local recurrence at a mean follow up of 24 months when all patients were alive. It does appear that the combination of PDT and brachytherapy for treating patients with lung cancer and CAO is safe and efficient. Sufficient time (approximately 4 weeks) should be allowed between radiation therapy and PDT to ensure that the radiotherapy-induced acute inflammation has subsided to avoid excessive necrosis and its undesirable consequences (broncho-esophageal or broncho-vascular fistulas). In fact, photofrin is contraindicated in patients with existing broncho or tracheo-esophageal fistulas and in patients with tumors eroding into a major blood vessel. It is also contraindicated in patients with porphyria. Treatment-induced inflammation can cause airway obstruction; thus, caution is warranted in patients with tumors in locations where treatment-induced inflammation can obstruct the main airway. Patients with hepatic or renal impairment may need longer precautionary measures for photosensitivity (possibly more than 90 days). PDT is not appropriate for emergency treatment of patients with severe respiratory distress caused by an obstructing lesion because approximately 40 to 50 hours are required between injection with photofrin and laser light treatment; in addition, the tumor necrosis and sloughing can compromise an already critically narrowed airway. PDT-related complications include skin burn, pneumonia, hemoptysis, and even respiratory distress requiring intubation (8). This latter complication is more likely when treating critical obstruction in the trachea or mainstem bronchi. Patients with endobronchial lesions must thus be closely monitored between the laser light therapy and the debridement bronchoscopy for any evidence of respiratory distress. Inflammation, mucositis, and necrotic debris may cause obstruction of the airway. If respiratory distress occurs, the healthcare team should be prepared to perform immediate bronchoscopy to remove secretions

and open the airway.

Conclusions: PDT for malignant airway obstruction requires understanding of basic PDT physics and safety principles. These depend on tissue characteristics (vascularization, oxygenation, prior thermal or radiation injury), PDT settings (e.g. power, fiber length) and operator-related factors (e.g. probe positioning). The goal of bronchoscopic PDT use in the malignant airway obstruction is to achieve the desired tumor destruction effects while minimizing damage to normal structures.

References

1. Barr H. Gut 2005; 54:875-884
2. Corti L. Lasers Surg Med. 2007; 39:394-402
3. Ross P. Lasers Surg Med 2006; 38 881-889
4. McCaughan JS Jr. J Thorac Cardiovasc Surg 1997; 114:940-6
5. Freitag L. Thorax 2004; 59: 790-793
6. Moghissi K. Eur J Cardiothorac Surg. 1999; 15:1-6
7. Diaz-Jimenez P. Eur Respir J 1999; 14: 800-805
8. Minnich D. Ann Thorac Surg 2010; 89:1744-9

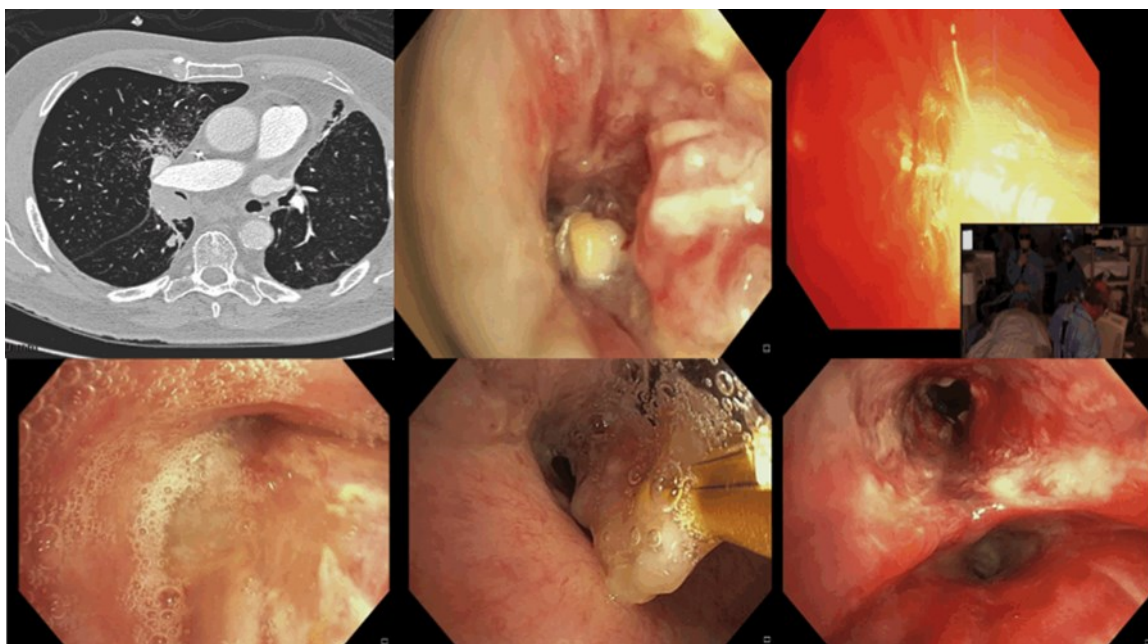


Figure 1. PDT applications: Bronchus intermedius obstruction noted on chest computed tomography but with evidence of ventilation of the right lower and middle lobes (top left); tumor nearly completely occluding the right bronchus intermedius before and during the PDT light application (top center and right panels). Tumor necrosis post PDT (day 5 post injection/day 2 post light application) (bottom left). Bronchial obstruction is relieved by flexible bronchoscopy and debulking with biopsy forceps (bottom center and right).



Masahide Oki, MD
Department of Respiratory Medicine
Nagoya Medical Center
Nagoya, Japan

TRANSBRONCHIAL PERIPHERAL LUNG NODULE SAMPLING

Introduction:

Bronchoscopy has been widely used as the first diagnostic procedure for peripheral lung nodules, but the low diagnostic yield of conventional bronchoscopy with or without fluoroscopic guidance has been considered unsatisfactory (1). Recent modifications to bronchoscopy using ancillary techniques, such as the use of a radial probe during endobronchial ultrasound (EBUS), navigation devices, and thin bronchoscopes have dramatically increased the diagnostic yield without compromising safety (2-5). The current trend to increase the accuracy of bronchoscopy seems to be the use of multimodal devices, in which each device plays an individual and complementary role (5). In our institution, we usually use thin bronchoscopes of ≤ 4.0 mm in diameter, virtual bronchoscopic navigation (VBN), EBUS, and fluoroscopy.

Indications:

We usually perform bronchoscopic biopsy on patients with a peripheral lung nodule requiring a definitive diagnosis to allow decisions relating to the management of the condition. Contraindications include very small nodules measuring < 8 mm in diameter, lesions with size instability by reviewing prior imaging tests, a high probability of nonspecific inflammation that is likely to diminish or disappear during surveillance, patients in poor physical condition for bronchoscopy (e.g., severe respiratory failure), and lesions for which other procedures (e.g., endosonographic needle aspiration) are easier to access.

Planning:

Before bronchoscopy, we create a virtual bronchoscopic pathway that indicates the bronchial route to the lesion by a VBN system (Bf-NAVI; Cybernet Systems, Tokyo, Japan) from the helical CT data with a 0.5- to 1.0-mm slice width. Even if the VBN is available, we always review the thin-slice CT to image the bronchial route to the lesion just before performing the bronchoscopy.

Sampling:

We perform bronchoscopic procedures under conscious sedation with an intravenous bolus of midazolam and fentanyl, and local anesthesia with lidocaine for the pharynx. An endotracheal tube with a 5.0-mm inner diameter is placed transnasally under thin bronchoscopic control, facilitating the repeated insertion and removal of the thin bronchoscope without rubbing the nasal mucosa or the vocal cords; this prevents the lens from becoming clouded and the channel from becoming plugged with mucus due to its relatively small working channel. Lidocaine is administered in the central bronchi using a spray catheter (PW-6C-1; Olympus, Tokyo, Japan), which gives improved anesthesia with less coughing compared with direct injection through the working channel. After examining the endobronchial region, the thin bronchoscope is advanced into the bronchus, which is indicated by VBN, as far as possible under bronchoscopic visualization (Figure 1A). The camera head of the C-arm fluoroscope is rotated to show the whole bronchial route to the target lesion transversely. This is followed by the introduction of an ultrasonic probe into the working channel; the probe is advanced toward the lesion under bronchoscopic control with fluoroscopic visualization (Figure 1B). The ultrasonic probe is adjusted to locate it within the lesion by manipulating the bronchoscope while moving the ultrasonic probe forward and backward under fluoroscopy. If the lesion surrounding the ultrasonic probe is clearly visualized by EBUS, the bronchus through which the ultrasonic probe passed can be considered the correct route to target the lesion. To localize the target lesion with EBUS or perform the biopsy repeatedly through the leading bronchus determined by EBUS, the thin bronchoscope should be advanced as close as possible to the target lesion. We usually use the ultrasonic probe or advanced biopsy forceps as a guide to further advance the thin bronchoscope (Figure 1C). After determining the leading bronchus, the ultrasonic probe is removed and transbronchial biopsies are performed under fluoroscopic guidance. When we use relatively small 1.5-mm biopsy forceps (6), approximately 10 biopsy specimens are taken from each lesion. This procedure is not performed under real-time EBUS guidance, so we confirm whether the biopsy forceps are advancing through the correct route using EBUS in the middle of the biopsies. After the biopsies, washing is performed using 5 to 20 mL of saline solution to allow for cytological and microbiological examination. A chest radiograph is obtained routinely to identify the presence of a pneumothorax 2 hours after the procedure.

Quality control:

It is well known that the diagnostic yield of EBUS-guided transbronchial biopsy is associated with the locational relationship between the ultrasonic probe and the target lesion on the EBUS image (3). Thus, we endeavor to insert the ultrasonic probe into the target lesion. The use of combined VBN and thin bronchoscopes with good bronchial selectivity and smooth maneuverability in the peripheral airway leads the ultrasonic probe to the center of the target lesion accurately and easily (5). Multimodal bronchoscopy is a complicated procedure and requires significant experience. In our institution, less experienced operators perform this procedure under supervision.

References

1. Rivera MP et al. *Chest* 2013; 143(5 Suppl):e142S-165S
2. Oki M et al. *Eur Respir J* 2008; 32:465-471
3. Oki M et al. *J Thoracic Oncol* 2009; 4:1274-1277
4. Oki M et al. *J Thoracic Oncol* 2012; 7:535-541
5. Oki M et al. *Am J Respir Crit Care Med* 2015; 192:468-476
6. Oki M et al. *Respiration* 2015; 89:235-242

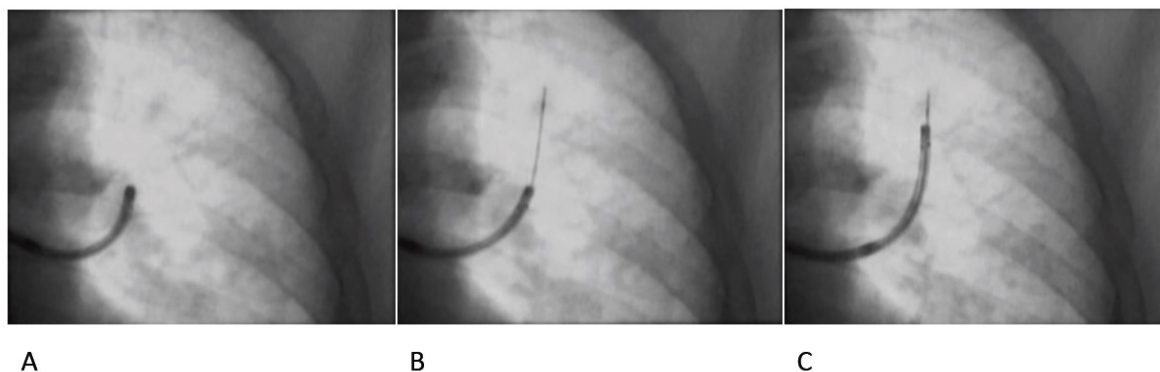


Figure 1. (A) The thin bronchoscope is advanced into the bronchus as far as possible, but does not reach the target lesion. (B) An ultrasonic probe is advanced toward the lesion under bronchoscopic control with fluoroscopic visualization. (C) The thin bronchoscope can be advanced further using the ultrasonic probe as a guide.

Humanitarian News

Humanitarian aid, the World Bronchology Foundation, and the WABIP

Last night I was at a national fundraiser for the American Heart Association. It was a tremendously successful meeting where all the attendees, speakers, and dinner guests seemed united behind one message: Funding research and education helps cure patients with heart disease and stroke. The success of such organizations, as well as that of other health-related foundations I have had the honor of being associated with: The Chest Foundation, the American Lung Association, Global Genes, and The Juvenile Diabetes Research Foundation made me think about our own international society, and our relationship with the World Bronchology Foundation (WBF), currently defined as the “philanthropic arm” of the WABIP.

Many WABIP members have little knowledge of the WBF, as I learned recently when several national leaders asked me to clarify the role of the WBF in our society. The Foundation was created ten years ago by Dr. Pablo Diaz, a prior Chair of the WABIP at a time before the WABIP had itself become a legally registered not-for-profit organization. The logo for the WBF was designed by Lorenzo Quinn, Italian sculptor and fifth son of Hollywood actor Anthony Quinn. The logo represents, in part, how the foundation assists patients by providing the equipment necessary to see inside the airways, and helping those in need with direct hands-on training. The Foundation’s initial board members included Henri Colt (USA), Silva Quadrelli (Argentina), Teresa Argemi (Spain), Ramon Rami-Porta (Spain), Patrick Barron (Japan), and Pablo Diaz (Spain). The WBF was registered in Barcelona, Spain as a nonprofit organization, and several attempts for fundraising were moderately successful to raise monies to sustain projects in Mozambique, Mauritania, Argentina, Bolivia, Ecuador, and El Salvador. Presentations about the Foundation were very well received at an American College of Chest Physicians meeting, as well as at two WABIP world congresses, where unfortunately, additional fund raising attempts prompted little enthusiasm.

During the next years, board officers changed according to the Foundation’s bylaws. The organization remains registered in Spain, where contributions to a nonprofit medical organization are not tax-deductible. The new officers are Drs. Enrique Cases Viedma (President, Spain), Carlos Disdier Vicente (Secretary Treasurer, Spain), Eduardo de Miguel Poch (Vice-president, Spain), Domingo Perez (Vice-president, Paraguay), and Silvia Quadrelli (Vice-president, Argentina). In accordance with the bylaws, Dr. Quadrelli will be replaced this year, and the board also includes two other positions belonging to the present Chair of the WABIP (Zsolt Papai, Hungary) and the current President of the next world congress (Eric Edell, USA).

Under this new leadership, ties with the AEER and SEPAR (Spanish pulmonary and endoscopy societies), and much to the credit of Drs. Enrique Cases and also Javier Flandes (WABIP regent for Spain), have been cemented, and the Spanish associations enthusiastically endorse planned WBF programs and agree to provide some funds to establish these programs. What then, does the WBF do? The original purpose of the WBF was to provide bronchoscopy equipment (for example, a flexible bronchoscope and light source), as well as targeted individual and team training to hospitals without adequate bronchoscopy services. The foundation has, however, been less successful than hoped in obtaining donations of preowned or otherwise redundant equipment from equipment manufacturers, hospitals, or individuals. Monetary donations to establish projects have also been lacking, as have fundraising events, making it difficult to meet Foundation’s objectives. Yet, members of the Foundation have identified several well known areas of need in Central America, Mongolia, Nepal, parts of Africa and many other regions of the world, where even a single flexible bronchoscope could change medical practice, so long as any donated equipment can be well maintained and procedures performed properly and after satisfactory training. The Foundation’s goals are to provide such equipment, and to help keep that equipment operative so as to favorably impact patient care.

As one can imagine, there are still other challenges facing the WBF. For example, while it is well known that several individual members of the WABIP are providing equipment aid and even donating their time to personally visit and help train physicians in foreign countries, the WBF has not yet tried to incorporate such individual endeavors into a programmatic approach that transitions into a WBF-sponsored or cosponsored project. There have been few attempts as of yet to reach out to organizations that partner with nonprofits donating equipment, such as large medical centers, private industry or charitable nonprofit groups such as MedWish, Healing Hands International, REMEDY, or ProC.U.R.E. Only once in the WBF's history has a collaborative grant been obtained (with the ACCP's CHEST Foundation), yet there are doubtless other opportunities to be seized, perhaps again with the ACCP, but also with other national and international organizations. The Foundation needs WABIP members to volunteer their efforts and ideas (as well as perhaps someday, their purses), to help advance the overall mission of the WBF, and to join the Foundation in its quest to provide greater patient access to flexible bronchoscopy equipment around the world. Finally, there is the challenge of defining the role of the WBF in its linked position with the WABIP, which since many years is a legally registered nonprofit entity in Japan, which is successfully providing humanitarian aid in the form of physician education and patient outreach. How can the WBF and WABIP work together, or should they be perceived as two separate entities with different goals and missions? Who should make these decisions? What projects might be undertaken? How can more funds be raised to sustain new projects, and should fundraising for new projects become the responsibility of the WBF, or of the WABIP?

These are just a few of the challenges facing us, and there is a world of opportunities ahead. The congress in Florence showed that we (now more than 6000 strong) are a growing number of concerned, involved, and expert proceduralists dedicated to patients with lung, airway and pleural disorders. Yet, physicians from many regions of the world are still not amply represented in our association. There are also many regions that need and desire greater access to flexible bronchoscopy, which is a "first technology" crucial to building a platform of procedure-based interventions that help patients with known or suspected cancer, airway obstruction, pulmonary infections, asthma, and COPD. Providing patients everywhere with access to such diagnostic and therapeutic procedures, in addition to helping physicians deliver competent care, providing equipment where otherwise there is none, and training health care teams in the safe and appropriate maintenance of that equipment, are goals well worthy of pursuit by our organization.



Figure 1: WABIP and WBF logos

**The views expressed in this article are those of the author and do not necessarily reflect the official positions of the Executive Board or International Board of Regents of the WABIP. Dr. Colt has consistently authored the Humanitarian, Education, and BOR News Section of the WABIP Newsletter and is Immediate Past-Chair of the WABIP.*

Education and Training

Item 1: Emerging educational technologies: BronchPilot Anatomy™ and BronchPilot Virtual™

Thanks to the hard work and professional contributions of dozens of colleagues, industry partners, organizing committees, congress participants (almost 1500!!), and experts from around the world, the Florence World Congress was informative, educational, fun, and motivating for all. The scientific program included didactic lectures and carefully designed symposia designed around central themes consistent with the subject of the world congress—"Interventional procedures in the context of multidisciplinary patient care." This congress not only cemented our growing organization's important place in the world of credible and influential professional medical societies, it highlighted our society's new image...an image of transparency, democracy, integrity, collegiality, and professionalism.

Among the many educational programs available at the World Congress, participants who stopped by the WABIP booth in the exhibit hall were able to experience firsthand two new learning instruments that have a serious and promising future in our quest for democratization of knowledge, and providing access to educational materials regardless of one's place of practice or residence. To complement our Fundamentals of Flexible Bronchoscopy learning programs (that include the highly successful Bronchoscopy Education Project with its interactive introductory courses, Train the Trainer programs, YouTube-based instructional videos, and WABIP-endorsed reading materials, checklists, and assessment tools), The WABIP showcased the iPad-based BronchPilot Anatomy™ and the Samsung/Oculus-based BronchPilot Virtual™ learning applications.

BronchPilot Anatomy is an iPad-based learning program built in collaboration with Sharp Vision Software with considerable input from Professor George Eapen (MD Anderson Cancer Center, Houston TX, USA) and other notable faculty from Bronchoscopy International. Available for purchase on the Apple iTunes store, the application has also been distributed free of charge to leading educators in dozens of countries, and forms the basis of our vision for *a Bronchoscopy University at your fingertips.* Using this application, the user can manipulate as needed a 3 dimensional replica of the airway and mediastinum (rotating airway and lymph node structures in space), examine vascular and lymph node anatomy on an adjacent computed tomography scan, all the while navigating through the lobar and segmental airways with a movable image of a flexible bronchoscope that flexes, extends and advances like a real scope. Users can simultaneously scroll through a written description of the anatomy, or access instructional videos and other learning materials by quick wireless links to key educational sites (instructional videos about BronchPilot Anatomy are available on the YouTube BronchOrg web channel: <https://www.youtube.com/watch?v=m7nUwt2iNyY>

Complementary to BronchPilot Anatomy™, is our Samsung/Oculus-based BronchPilot Virtual™ learning application. Using an Oculus virtual reality headset and a Samsung Galaxy phone, the application allows total immersion. Users become the flexible bronchoscope as they navigate through the airway, visualizing anatomic structures and in-transparency mediastinal lymph nodes. A series of labels (road signs) point to the various structures. Users can choose to go on a 4 minute "guided tour" while listening to a detailed narrative of anatomic structures, or perform a self-guided exploration of the tracheobronchial tree by simply looking at key road signs along the way, then advancing or retreating toward the target sign. Within minutes (and even faster than when using BronchPilot Anatomy™), users become instinctively familiar with airway anatomy and lymph node location. This virtual reality learning tool allows users to gain knowledge at the own pace and using their own time, while also developing instinctual and real-to-life reflex movements that translate the manipulations required to perform an airway inspection with a real flexible bronchoscope! Stay-tuned for an exciting instructional video soon on the YouTube BronchOrg web channel!

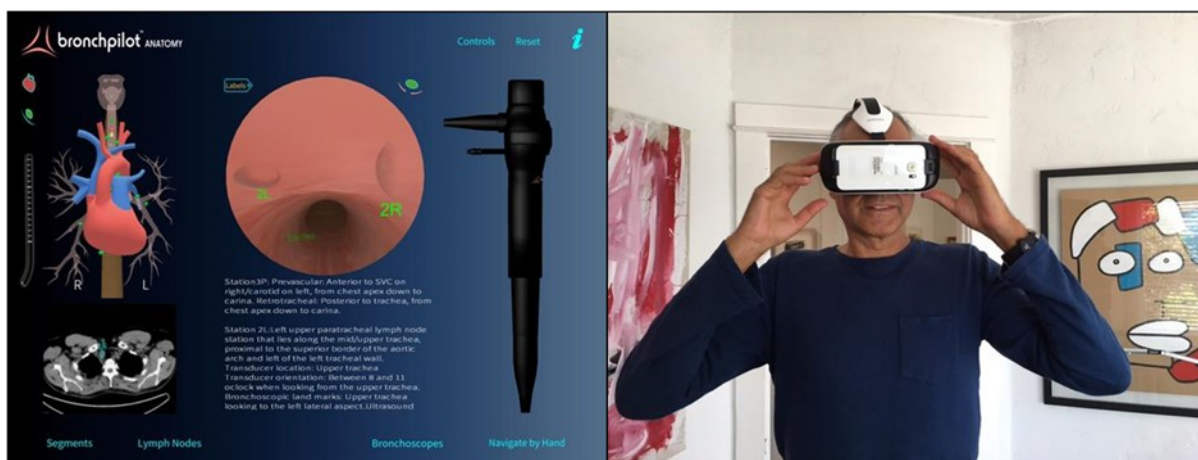


Figure 1: Screenshot of iPad-based BronchPilot Anatomy™ and Bronch Pilot Virtual™ user wearing Samsung/Oculus headset

Education and Training

Item 2: Emerging educational technologies: The WABIP Image and Literature Libraries

The World Congress was the site of our first WABIP Academy (<http://www.wabipacademy.com/>) dedicated symposia chaired by Drs. Herve Dutau (Marseille, France, Section head, Image Library) and Roberto Casals (Houston, USA, Section head, Literature Library). These symposia will become regular events at all future WABIP World Congresses, and plans are already beginning on the construct of greater interactivity with an international (onsite- and distant) audience during the World Congress scheduled for Rochester in June 2018. Accessible on the WABIP website, **The WABIP Literature Library** contains 3-5 pertinent articles from peer reviewed literature (original research papers and review articles) beginning in 2012. Each article is followed by a short multiple-choice test for future Continued Medical Education credit purposes. **The WABIP Image Library** contains a growing number of bronchoscopic and pleural images categorized by disease type and airway or pleural abnormality. We (the WABIP executive, CME, and education committees) are in the process of investigating how European (EACCME) credits might be obtained after viewing library content.



Figure 2: Screen shot of webcast page on the new WABIP Academy webpage at www.wabip.com

ITEM 3: Bronchoscopy Education Project and new translations of *The Essential Flexible Bronchoscope*®

Since the recent introduction of the new *Essential cTBNA Bronchoscope*® (English and Spanish translations) members from Romania and Italy translated *The Essential Flexible Bronchoscope*® into Romanian and Italian. We want to officially thank Drs. Marioara Simon, Lorenzo Corbetta, and their teams for this diligent work. PDF formatted eBooks are available on the WABIP website (<http://www.wabipacademy.com/publications/eb>) as well as on the Bronchoscopy International website (www.Bronchoscopy.org) for free download.

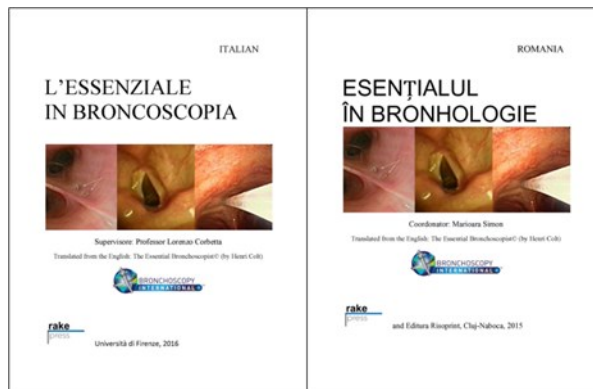


Figure 3: Italian and Romanian translations of *The Essential Flexible Bronchoscope*®

Congress News

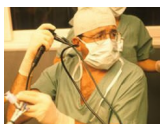The World Congress in Florence, Italy was a great success with more than 1,300 participants from over 50 countries, a record number of scientific abstracts, video award entries, excellent industry support, and an all-star academic and social program. There was nothing but praise from all of the attendees.

There were 59 Symposia for WCBIP and 12 Symposia for WCBE, plus 4 key note lectures for WCBIP and 6 key note lectures for WCBE. Furthermore, there were 5 breakfast lessons from mentors. Among the Symposia, there were 2 Joint Symposia WABIP/IBES, 1 joint Symposium WABIP/ERS, 1 Joint Symposium WABIP/AABIP and 1 Joint Symposium WABIP/AIPO.

The scientific committee received 400 abstracts (from 50 countries), 220 of which were eligible for the Becker Awards. This year we had 4 award categories and recipients are:



Killian Medal - Kazuhiro Yasufuku



Dumon Award - Masahide Oki



Becker Awards - Rosaria Carrinola, Melissa Suter, Bojan Zaric



Lifetime Achievement Award - Sergio Cavaliere

There were 26 videos submitted for participation in the WCBIP/WCBE Video Festival. Of these videos, the Awards were presented to: Nikos Koufos (Best Imaging), Takahiro Nakajima (Best Innovation), Tajalli Saghale (Best Scientific Content), Jonas Yserbyt (Best Overall Video).

Board of Regents News

We are pleased to announce that the Board of Regents meeting on May 8th in Florence was a great success. 40 voting board members attended (out of 57 possible regents). The board elected a new Vice-Chair (Dr. Silvia Quadrelli of Argentina), and selected Marseille, France to host the 2022 World Congress (Prof. Philippe Astoul as WCBIP President).

As the new term begins, many of our colleagues' tenure on the Board of Regents have concluded. Some of the past BOR members were effectively succeeded by new colleagues who are: Andarini, Sita (Indonesia), Becerra, Elizabeth (Peru), Chima, Kamran (Pakistan), Comert, Sevda (Turkey), and Santosham, Rajan (India). We welcome these new members into our Board.

Call for WABIP Committee Members:

On behalf of the Executive Board and the WABIP Board of Regents, we thank all those who served as committee chairs and members from 2012-2016. New committee vacancies and assignments are listed on the website here (<http://www.wabip.com/forms/committees>). If you are interested in serving on a committee, please go to the above link and submit your application for consideration. Thank you all for supporting the WABIP!



Editorial Staff



Associate editor: Dr. Ali Musani

Editor-in-Chief: Dr. Kazuhiro Yasufuku

Primary Business Address:

Kazuhiro Yasufuku, Editor-in-Chief

WABIP Newsletter

c/o Judy McConnell

101 College St., TMDT 2-405

Toronto, Ontario M5G 1L7

Phone: 416-581-7486

E-mail: newsletter@wabip.com



Associate editor: Dr. Septimiu Murgu

Research

Favorites from Florence

Cutting Edge Research Presented at the World Congress of Bronchology 2016

Sedation for Bronchoscopy

Optimal sedation of patients undergoing flexible bronchoscopy remains a big issue. With the advent of minimally invasive diagnostic and therapeutic procedures, this question is evermore critical. The question emanates from many aspects including, the preference of the bronchoscopist, the anesthesiologist, and the patient. They are all equally important issues along with other issues such as what helps achieve the best outcomes from the procedure, improves throughput, and works for the economic model of the institution.

The study (1) from India has tried to answer some of these fundamental questions. In this study the authors compared the use of Midazolam, Fentanyl, combined Midazolam – Fentanyl and Propofol sedation and looked at oxygen desaturation, hemodynamic changes, Physician satisfaction, patient tolerance and feasibility of procedure as the outcomes. One hundred twenty patients were randomized into the groups mentioned above. However, the details of the procedures performed such as endobronchial ultrasound, navigation, transbronchial biopsy, endobronchial biopsy etc. were not mentioned. Physician reported feasibility, physician satisfaction, cough scores, and overall procedure satisfaction scores were highest for combined sedation group. However, Patient reported tolerance of bronchoscope insertion was best for Propofol group.

As expected, these results are inconclusive but suggest a trend in favor of moderate sedation with a major limitation of not knowing the specific procedures done. A prospective study with details of specific procedures and doses of drugs would be very helpful.

Sonographic Features of Mediastinal Lymph Nodes with EGFR mutation

In the pursuit of perfection in endobronchial ultrasonography, the researchers are looking beyond just accurately obtaining the biopsy of the mediastinal lymph nodes. They are now looking at the internal structures, echoes and other micro environment of the lymph nodes to glean information as to the type of disease involving the nodes and minute details such as genetic mutations of the cancer. These mutations, when present can have significant implications of personalized cancer therapies and improved outcomes.

In this retrospective study (2) of 75 patients, diagnosed with adenocarcinoma of the lung by Endobronchial Ultrasound (EBUS) guided Transbronchial Aspiration (TBNA), researchers looked at the lymph node feature such as size, shape, margin, echogenicity, necrosis, matting and vascular patterns to find characteristics to suggest specific genetic mutation(EGFR). Correlations between cytology and histopathology of EBUS

Research

samples were in 14(70%) in EGFR (+), 38(76%) in EGFR (-). It might be possible one day to look at the Sonographic features of the lymph nodes and accurately predict the malignancy, cell type, and genetic mutation status without biopsy. It may sound farfetched at this point in time but again, did we think we would diagnose a fatal disease like interstitial pulmonary fibrosis without biopsy, just based on radiographic features. Did we think planes will fly without pilots and cars will drive without drivers?

Drug Eluting Airway Stents Could Reduce Granulation

Regardless of the indication for an airway stent placement, formation of granulation tissue in and around the stent remains a concern. It is substantially more with metallic vs silicone and uncovered metallic vs covered metallic stents. Hence, the black box warning on the use of metallic stents in benign diseases by the Food and Drug Administration in USA.

In this canine study (3), tracheal drug eluting and non drug eluting metallic stents were placed in a randomized fashion in 6 dogs. Proliferation of granulation tissue and changes of tracheal mucosa between two groups were compared. The drug eluting stents were loaded with Paclitaxel, which slowly released in the tissue over months after placement. Paclitaxel levels were measured in the serum and in the tracheal and lung tissue. The researchers report a significant decrease in the formation of granulation tissue in the drug eluting group compared to non-drug eluting group and lack of any adverse effects locally or systemically due to antifibroblastic properties of Paclitaxel eluted from the stents.

If similar results can be reproduced in humans with benign and malignant airways strictures, we might be able to enjoy the ease of placing, high conformability and other qualities of the metallic stents. Particularly, in benign conditions where stent removal is desired but dreaded due to exorbitant granulation associated with metallic stents.

References

1. Comparison of Medazolam, Fentanyl, Combined sedation and Propofol for transnasal Bronchoscopy: V Patel, M Bhandari, et al: Intervention Pulmonary Medicine, Chest Disease Clinic, Sparsh Hospital – India
2. Clinical and Sonographic Features According to EGFR mutation in Lung Adenocarcinoma by EBUS-TBNA. Y M Lee. Pulmonary Dept. of Medicine, Busan Paik Hospital, Inje University - South Korea
3. Animal Studies about The Inhibition Function of Paclitaxel Drug-eluting Stent on Trachea-restenosis. T Wang, J Zhang et al: Department of Respiratory, Beijing Tiantan Hospital, Capital Medical University – China

UPCOMING EVENTS

5th Annual EBUS and Advanced Diagnostic Bronchoscopy (USA)

When: July 21-22, 2016

Where: Hyatt Regency Chesapeake Bay, Cambridge, Maryland, USA

Program Director: Lonny Yarmus, DO, FCCP

Program Type: Hands-on workshop, Conference (didactic lectures)

Program Schedule: <http://www.wabip.com/images/articles/EBUSProgram%202016.pdf>

11th Annual Midwest Introductory Bronchoscopy and Pleural Procedures Course (USA)

When: July 21-22, 2016

Where: Mayo Clinic, Rochester, MN

Program Director: John Mullon, MD

Program Type: Educational seminar (for trainees only), Hands-on workshop

Program Schedule: <https://www.wabip.com/uploads/endorsements/5740b2c7a424b-Course%20Schedule%20Bronch%20Pleur%20Course%202016.doc>

Current Practices and Future Directions in Pulmonary, Critical Care and Sleep Medicine: The 14th Year (USA)

When: 8/11/16 - 8/14/16

Where: Hilton Santa Fe Historic Plaza, Santa Fe, NM

Program Director: Lonny Yarmus, DO, FCCP, MD

Program Type: Hands-on workshop, Conference (didactic lectures).

Program Schedule: [https://www.wabip.com/uploads/endorsements/5746ead458247-Pulmonary%20Broch%2016_%20\(002\).pdf](https://www.wabip.com/uploads/endorsements/5746ead458247-Pulmonary%20Broch%2016_%20(002).pdf)

Malaysian Assembly Of Bronchology And Interventional Pulmonology (Malaysia)

When: 29-30 September 2016

Where: Kota Kinabalu, Sabah, Malaysia

Program Director: Dr Kunji Kannan A/I Sivaraman Kannan

Program Type: Hands-on Workshop, Conference (didactic Lectures)

WABIP ACADEMY- WEBCASTS

The WABIP has started a new education project recently: *THE WABIP ACADEMY*. The WABIP Academy will provide free online webcasts with new and hot topics that will interest pulmonologists and interventionalists.


Current webcast topic: **Tissue acquisition for biomarker directed therapy of NSCLC**


Webcast


Small Sample Tissue Acquisition and Processing for Diagnosis and Biomarker-driven Therapy of NSCLC

Welcome to WABIP's free online learning tool to increase knowledge regarding the appropriate selection, acquisition, and processing of cytology and histology samples from patients with known or suspected lung cancer.

Click an icon to begin


Program Description


Purpose


General Learning Objectives



Specific Learning Objectives


TABLE OF CONTENTS >

Each fictitious clinical case scenario is based on a conglomerate of real patient data. Cases have been modified to avoid any possibility for patient identification and to help meet educational objectives. Any resemblance to real persons, living or deceased, is purely coincidental.

The content for these webcasts has been developed by members of the World Association for Bronchology and Interventional Pulmonology. All content was reviewed by an independent multidisciplinary team of experts. Unless otherwise specified, all content is the property of WABIP.

A collaborative project with Pfizer Oncology

Credits >



You can reach these webcasts by using this link: <http://www.wabipacademy.com/webcast/>

Links

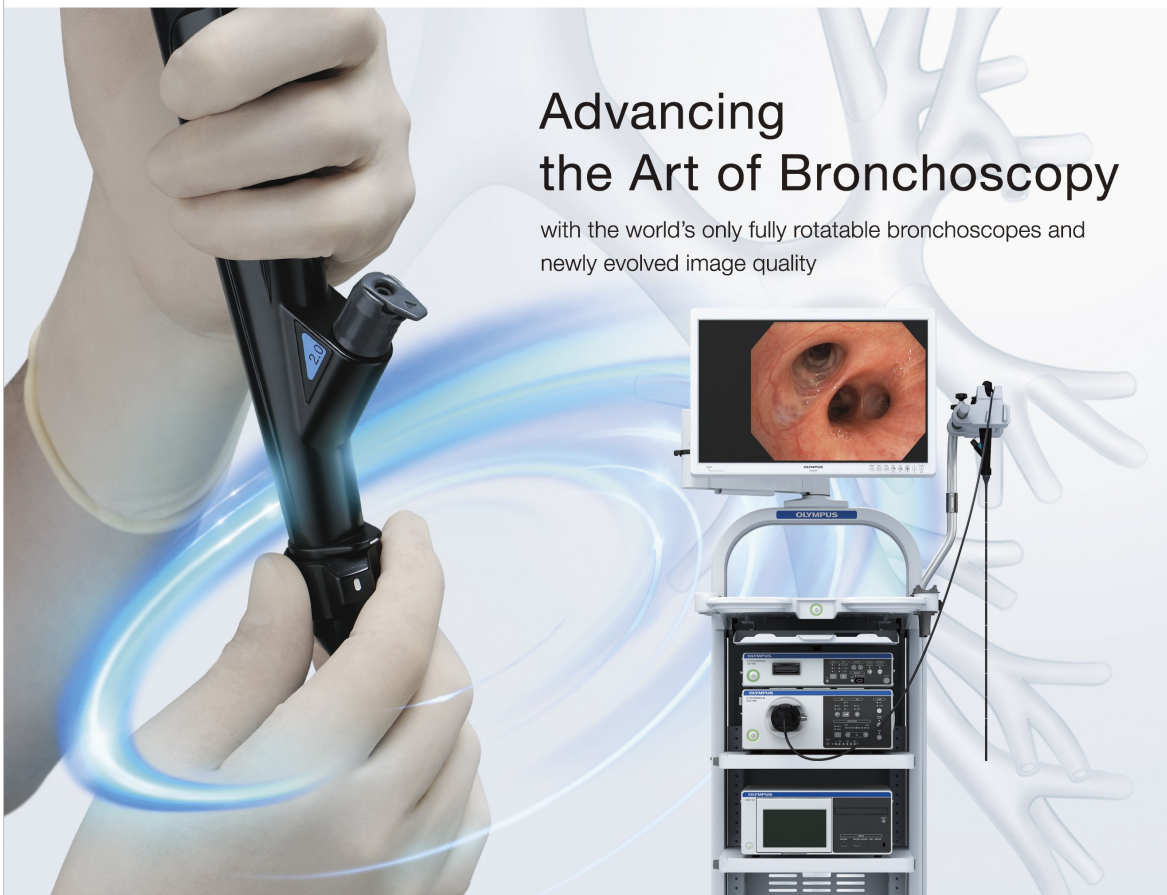
www.bronchology.com	Home of the Journal of Bronchology	www.chestnet.org	Interventional Chest/Diagnostic Procedures (IC/DP) NetWork
www.bronchoscopy.org	International educational website for bronchoscopy training with u-tube and facebook interfaces, numerous teaching videos, and step by step testing and assessment tools	www.thoracic.org	American Thoracic Society
www.aabronchology.org	American Association for Bronchology and Interventional Pulmonology (AABIP)	www.ctsnet.org	The leading online resource of educational and scientific research information for cardiothoracic surgeons.
www.eabip.org	European Association for Bronchology and Interventional Pulmonology	www.jrs.or.jp	The Japanese Respiratory Society
		sites.google.com/site/asendoscopiarespiratoria/	Asociación Sudamericana de Endoscopia Respiratoria

OLYMPUS®

Your Vision, Our Future

Advancing the Art of Bronchoscopy

with the world's only fully rotatable bronchoscopes and
newly evolved image quality



OLYMPUS pursues perfection in the art of bronchoscopy with major advances in maneuverability and visualization.

Advancing Maneuverability

New features including Insertion tube rotation function, improve handling and in-procedure maneuverability of bronchoscopes.

Advancing Visualization

The new HDTV bronchoscopes achieve an outstanding level of clarity and detail enabling the bronchoscopist to perform more precise observation and diagnosis.

EVIS EXERA III

**EVIS LUCERA
ELITE**

OLYMPUS MEDICAL SYSTEMS CORP.
Shinjuku Monolith, 2-3-1 Nishi-Shinjuku, Shinjuku-ku, Tokyo 163-0914, Japan

* EVIS EXERA III and/or EVIS LUCERA ELITE are not available in some areas

BT.
Because their world
is bigger
than their asthma.

**Boston
Scientific**
Advancing science for life™

Bronchial Thermoplasty (BT) is an
established procedure for severe asthma
proven to reduce exacerbations for at least **5 years**.¹

79%

responder rate in improved
asthma-related quality of life.²

Global societies and organizations support BT
as an option for patients with severe asthma.

GINA • ACAAI • INTERASMA
BTS • GEMA • NICE • CHEST

For more information visit **www.BTforAsthma.com**

¹ Wechsler M et al. J Allergy Clin Immunol. 2013 Dec;132(6):1295-302.

² Castro M, et al, for the AIR2 Trial Study Group. Am J Respir Crit Care Med. 2010;181:116-124

CAUTION: The law restricts these devices to sale by or on the order of a physician. Information for the use only in countries with applicable health authority product registrations.

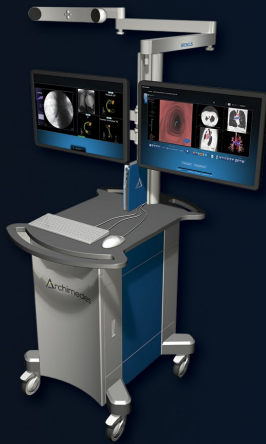Indications, Contraindications, Warnings and Instructions for Use can be found in the product labeling supplied with each device.

All trademarks are the property of their respective owners. © 2016 Boston Scientific Corporation or its affiliates. All rights reserved. ENDO-371010-AA January 2016

 **Bronchial
Thermoplasty**



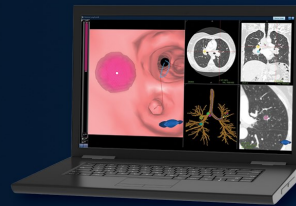
Delivering Navigation Diagnostic and Therapeutic Technologies to Treat Patients with Lung Disease



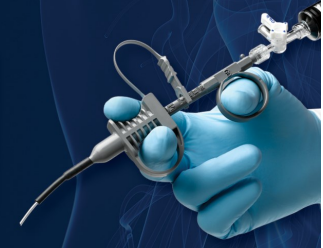Archimedes™ Next Generation
Pulmonary Navigation Technology



Lungpoint® Virtual
Bronchoscopic Navigation System



LungPoint®
Satellite Planning System



FlexNeedle® Multipurpose
18g Coring Needle

MK-340 Rev. 10/13

+1 650.428.1600 • sales@broncus.com • www.broncus.com

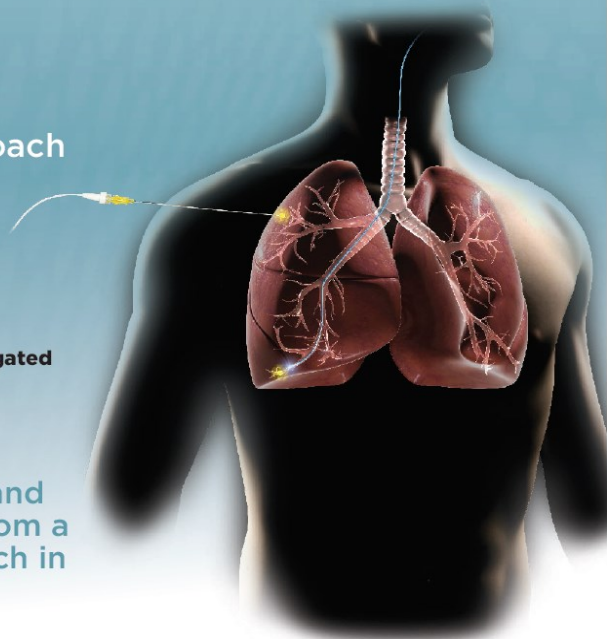
For More Information

SPiNPerc:

Navigated Percutaneous (TTNA) Approach for Peripheral Targets

- Target the 40% of nodules that lie outside of an airway
- Only proven cost-effective patient care pathway:
All in One procedure*
- Seamlessly transition from navigated bronchoscopy to navigated percutaneous TTNA

SPiNPerc™ makes it possible for lung physicians such as thoracic surgeons and pulmonologists to quickly transition from a bronchoscopic to a percutaneous approach in one procedure.



* Lee, K. Adam, MD, Abhjit A. Ravei, MD, and Leah Amir, MD. Cost Effectiveness of Endobronchial Percutaneous Biopsy Compared to Transthoracic Biopsy for Diagnosis of Peripheral Lung Lesions (2014). MK-097

314-659-8500
www.VeranMedical.com

Driving Innovation. Impacting Lives.



RETHINK
LUNG
HEALTH

More than an ENB[†] system, Medtronic and **superDimension™** provide a comprehensive lung health program resulting in higher yields, earlier diagnosis and better patient health outcomes.*

*Data on File, 2014.
† Endobronchial Navigation Bronchoscopy.
Currently licensed under superDimension Inc.
© 2015 Medtronic. All rights reserved.
Medtronic, Medtronic logo and Further, Together are trademarks of Medtronic.

Medtronic