WABIP Newsletter

Volume 10

Issue 02

MAY 2022

Inside This Issue

WABIP Newsletter

VOLUME 10, ISSUE 2 MAY 2022

Patients with Complex Tracheal Disease Benefit from a Multidisciplinary Airway Team

Ajay Wagh[1], Brandon Baird[2], Maria Lucia Madariaga[3], Elizabeth Blair[2], Septimiu Murgu[1]

[1] Section of Pulmonary and Critical Care Medicine/Interventional Pulmonology, Department of Medicine, The University of Chicago, Chicago, IL, USA
[2]Section of Otolaryngology, Department of Surgery, The University of Chicago, Chicago, IL, USA
[3]Division of Thoracic Surgery, Department of Surgery, The University of Chicago, Chicago, IL, USA

***Cor**respondence to: Ajay Wagh. Division of Interventional Pulmonology, The University of Chicago, 5841 S Maryland Ave, Chicago, IL 60637, USA. Email: awagh@medicine.bsd.uchicago.edu.*

Not uncommonly patients who present with dyspnea, wheezing, cough, or other respiratory symptoms are initially diagnosed as having asthma or COPD, but ultimately found to have tracheal stenosis. This can be secondary to a number of conditions including but not limited to mechanical injury (e.g. post intubation, post tracheostomy) as well as connective tissue disease, inhalational injury, radiation, and infections (post tuberculosis, viral or tracheitis from Klebsiella rhinoscleromatis or other organisms). These tracheal abnormalities are found in patients with varying comorbidities and many times present in the form of firm fibrotic cicatrix, which vary in degree of obstruction, length, morphology, and location, specifically the distance from the cricoid cartilage. As such, collaboration within a multidisciplinary team of physicians with expertise in different techniques involving otolaryngologists, thoracic surgeons, and interventional pulmonologists ensures the most optimal management for individual patients. In multidisciplinary airway team meetings and clinics, the teams consider different methods for management of tracheal diseases including medical management alone, endoscopic incisions and dilation, stenting, or open surgical resection (Figure 1).

Multidisciplinary management of complex airway cases includes regular conferences to discuss these patients and review their CT scans, laryngoscopy and bronchoscopy videos. This is often followed by shared clinics for further evaluation and joint procedures in the operating room. Like other centers across the world, at the University of Chicago we have developed a formal Complex Airway Disease Center, where patients are evaluated by our multidisciplinary team of physicians including interventional pulmonology, ENT, and thoracic surgery. Cases are reviewed at a monthly conference for shared decision-making and planning purposes. Notably, collaborative management in the operating room is also frequently utilized for both airway assessment and therapeutic management. In some cases, airway patency has to be restore emergently via rigid bronchoscopy but an evaluation by a surgeon can be performed simultaneously, especially for patients who are known to have complex stenosis and are otherwise surgical candidates (Figure 2). Other times, otolaryngology manages the subglottic laryngeal disease or performed suspension laryngoscopy with jet ventilation, while IP manages the tracheal component, especially in inoperable patients with extensive, multifocal disease or those with acute necrotizing tracheitis casing airway compromise (Figure 3). Additionally, monthly meetings are held with long-term acute care hospital partners to ensure optimal follow up for patients who may get transferred to such a facility (especially post tracheostomy patients). We have recently proposed an algorithm of multidisciplinary care which is utilized by the members of our team (Figure 1) (1).

Another important service of the multidisciplinary complex airway care team is to manage patients who develop short or long-term tracheostomy-related adverse events. These patients require careful management to ensure optimal management of any tracheostomy-related issues including but not limited to stomal strictures, subglottic stenosis, stenosis/granulation distal to the tracheostomy and trachea-esophageal fistulas. For inpatients, allied healthcare providers (nurses, physician assistants, or respiratory therapists) with specialized training in tracheostomy management should be involved for a consistent follow up and early detection of any tracheostomy-related issues and to assure an optimal post procedure management (downsizing the tracheostomy tube, capping trials, decannulation). Additionally, speech and language pathologists are integral members helping patients to resume speech function. Studies have described the approach to implementation of tra-

cheostomy specialists and have demonstrated improved outcomes with fewer complications and critical incidents. Tracheostomy specialists can also help to educate other staff members in tracheostomy management (2, 3). Since the beginning of COVID-19 pandemic, there has been even more of a need for careful tracheostomy management from specialized care teams as described (4, 5).

Like in other areas of medicine, such as thoracic oncology, engaging a multidisciplinary team of professionals with different educational backgrounds and skillsets can help offer optimal management for complex airway patients. The group can also collaborate and provide long term follow up care required to ensure airway stability, evaluate for recurrence in setting of malignancy resection, and to help mitigate any potential complications.

References:

1. Agrawal A et al. Respir Med. 2021;187:106582.

2. Crosbie R et al. J Laryngol Otol. 2014;128(2):171-3.

3. Norwood MG et al.. Postgrad Med J. 2004;80(946):478-80.

4. Meister KD et al. Otolaryngol Head Neck Surg. 2021;164(5):984-1000.

5. Lamb CR et al. Chest. 2020 Oct;158(4):1499-1514.

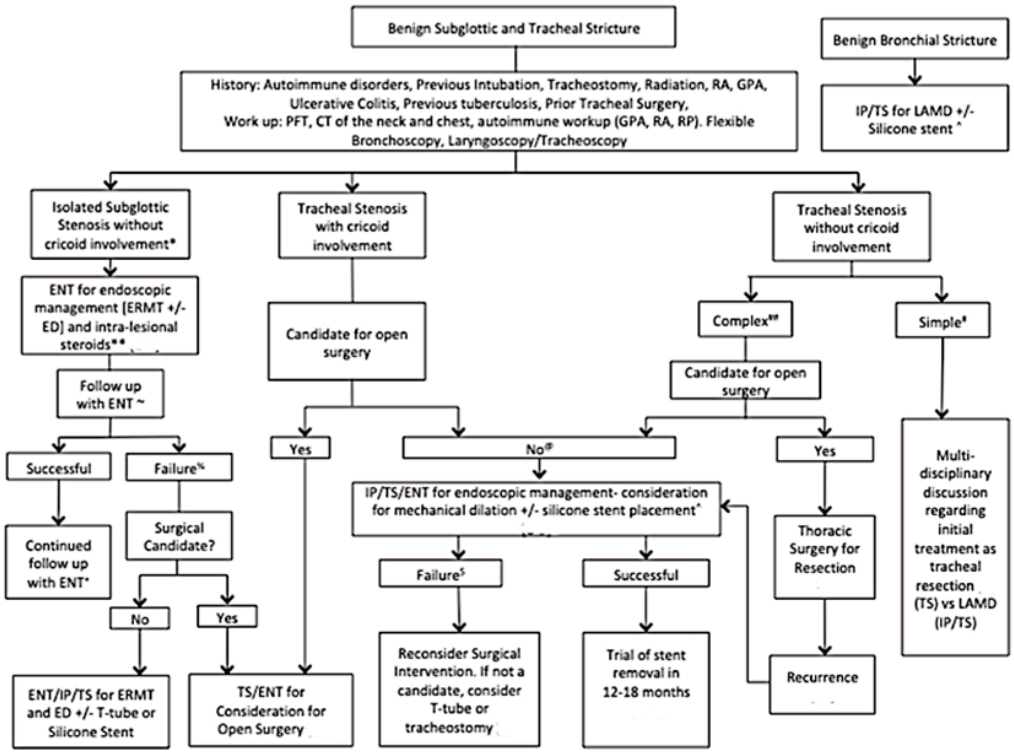

Figure 1. Multidisciplinary Benign tracheal stricture management per Agrawal et al (1). Used with permission from Elsevier.

A Multi-disciplinary Management Algorithm in Patients with Benign Airway Strictures Mechanical Dilation: LAMD (Laser Assisted Mechanical Dilation) or Cold Knife Assisted Mechanical Dilation. ERM'T: Endoscopic resection (+/- Wedge Approach) with adjuvant medical therapy (PPI, ICS and TMP/SMX). ED: Endoscopic Dilation, ENT: Ear, Nose & Throat Surgery, IP: Interventional Pulmonology, TS: Thoracic Surgery. *This algorithm applies only to idiopathic subglottic stenosis (iSGS). For patients with connective tissue disorders, first treatment option will be endoscopic management due to high recurrence rate post-surgical resection. ** Endoscopic management depending on severity of symptoms. Patient will undergo radial incision with or without mechanical dilation. ~ Outpatient follow up with ENT including outpatient laryngoscopy and in-office injection of intralesional steroids. % Failure defined as patients requiring more than 3 interventions over 2-3 years with symptomatic recurrence and >50% stenotic index, despite office-based intralesional corticosteroid injection. + Consider use of office based intralesional steroid injection to maintain patency and reduce time to re-intervention. *# Complex: Longer> 1 cm, with or without chondritis. # Simple: Less than 1 cm in size, without chondritis. @ Factors affecting surgical candidacy include multiple comorbidities, prolonged steroid use, stricture location, or long vertical extent (>4-6 cm). § Failure defined as repeated procedures including recurrent stent migration, followed by symptomatic recurrence of stenosis. All patients with airway stent will follow the stent protocol defined below. Stent Follow-up Protocol: Flexible Bronchoscopy with moderate sedation 4-6 weeks post stent placement. Follow up bronchoscopy every 2-3 months or based on clinical symptoms. 0.9% Normal saline nebulizer 5-10 ml TID. Stent card & Stent education.

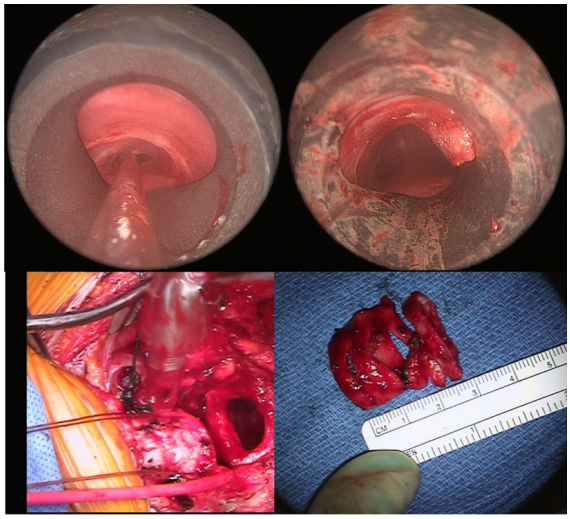

Figure 2. Severe PITS in a patient with respiratory distress seen during rigid bronchoscopy (top left). Laser assisted mechanical dilation restored airway patency (top right). At the time of recurrence, the patient underwent surgical resection. The left bottom left panel shows the marked proximal and distal aspects of the stenosis. The excised tracheal stenosis segment of ~ 3 cm is seen on the bottom right panel.

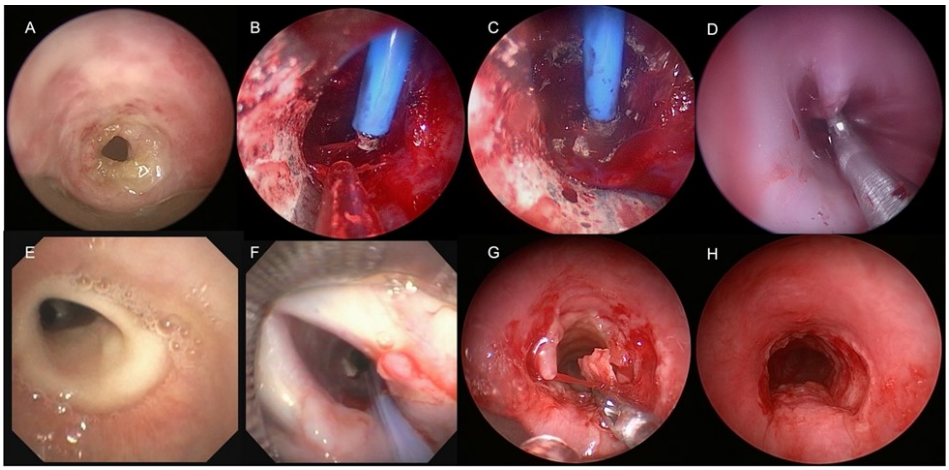

Figure 3. Top panel. Severe tracheal stenosis developed distal to the tip of a tracheostomy tube (picture A taken after the tracheostomy tube was removed). Post dilation, a mucosal tear caused bleeding from the posterior tracheal wall which was successfully coagulated using electrosurgery via tracheal stoma by the ENT surgeon (B and C). Then a T tube was inserted and via rigid bronchoscopy using rigid forceps, the bronchoscopist assist in opening up the infra-stomal arm of the T tube (D). Bottom panel: E. severe symptomatic pseudomembranous tracheal stenosis immediately post extubation seen during flexible bronchoscopy. F. Suspension micro-laryngoscopy was performed by the ENT surgeon with Jet ventilation. G. Rigid bronchoscopic debridement of the pseudo-membranes is performed. H. Then the stricture is dilated and airway patency is restored.

Technology Corner

3D Printing for Surgical Planning for Subglottic Airway Stenosis


Thomas Schweiger, MD, PhD,[1] Kazuhiro Yasufuku, MD, PhD,[2]
Konrad Hoetzenecker, MD, PhD[1]

1 Department of Thoracic Surgery, Medical University of Vienna, Austria.
2 Division of Thoracic Surgery, Toronto General Hospital, University Health Network, Toronto, Ontario, Canada

Introduction

The surgical treatment of subglottic cicatricial stenosis remains one of the most challenging fields in airway surgery. In addition to the estimated resection length, the proximity of the stenosis to the vocal folds is the main characteristic dictating the appropriate surgical technique. Not only a complete resection of the cicatricial tissue, but also preservation and restoration of the functional capacities of the larynx should be achieved. In general, the pre-operative work-up in patients with airway stenosis should at least consist of a computed tomography (CT) and bronchoscopy. However, even for experienced surgeons the pre-operative judgement of the exact extent of the stenosis and the required surgical repair remains demanding, especially in subglottic pathologies.

Background

Additive manufacturing and three-dimensional (3D) printing is nowadays broadly available. Consequently, a growing number of possible medical applications has been described. Especially in the diagnosis and treatment of airway pathologies, a variety of possible applications were described by various institutions world-wide (1-4). Beyond manufacturing customized, patient-specific implants such as airway prosthesis (4), the transition of two-dimensional CT images into 3D-printed, haptically perceptible models changed the possibilities of teaching and planning complex surgical procedures (5). For instance, 3D-printed models of centrally located lung cancer can be used to teach surgical residents the principles of bronchial sleeve resections (6). Using materials with similar rigidity and elasticity as the human airways, bronchial sleeve resections were even simulated in a simplified, but anatomically correct way during dry lab trainings. Similarly, 3D printed models can also be used to plan complex resection at the laryngotracheal junction.

Dependent on the extent of subglottic stenosis in relation to the anatomical structures, various surgical techniques have been described. Cricotracheal resection including a partial resection of the cricoid arch and the first tracheal rings is considered the basic technique to address a stenosis, which is limited to the anterior portion of the cricoid. A dorsal mucosectomy at the cricoid plate has to be added to the procedure, as soon as the scarification of the mucosa or submucosa is present at the dorsolateral portion of the cricoid. This involvement is rather typical in patients suffering from an idiopathic subglottic stenosis. The most complex type of subglottic stenosis reaches the vocal fold and is therefore described as glotto-subglottic stenosis. If a complete resection by means of a cricotracheal resection with a very extended dorsal mucosectomy is not resulting in a sufficient subglottic lumen, the larynx has to be enlarged by the interposition of cartilage anteriorly and/or posteriorly.(7) Although the ultimate decision which of these techniques has to be made during the surgical procedure, experienced airway surgeons will be able to predict the necessary surgical technique with a very high accuracy. However, students, residents and surgeons not experienced in airway surgery usually exhibit difficulties in merging bronchoscopic findings with the corresponding CT images. Subsequently, the incorrect classification of the airway stenosis negatively affects planning the appropriate surgical procedure.

Clinical Application

We could previously demonstrate the value of 3D-printed models over conventional CT images or bronchoscopy in patients with subglottic stenosis. (8) In this work, the study participants were divided into subgroups dependent on the level of experience in airway surgery (residents vs. fellows or non-airway surgeons vs. dedicated airway surgeons). Participants were provided with bronchoscopy videos, conventional CT scans or 3D-models of 19 patients with subglottic stenosis and asked to classify the stenosis and to choose the appropriate surgical technique for resection. Residents and fellows/non-airway surgeons benefited most from the 3D models which significantly improved their diagnostic accuracy. Interestingly, the group of experienced airway surgeons achieved almost a similar high accuracy by sole evaluation of bronchoscopy videos. Two-dimensional axial CT images were of least value throughout all study groups. This study illustrated the potential benefits of 3D models when treating patients with subglottic stenosis. Moreover, these models might be of value in patient education and when obtaining informed consent for laryngotracheal resections. 3D models could be used to illustrate specific surgical procedures and possible functional implications after surgery to the patient. However, there also several issues limiting the clinical applications of these 3D printed models. First, processing of the raw imaging data to delineate the stenosis from the individual anatomical structures and multi-color printing requires a degree of knowledge and resources, which are not available at every institution. Moreover, manufacturing a 3D model for each individual patient referred for surgery would most likely exceed these capacities even if present and established. The time needed from imaging acquisition to the production of a model is rather weeks than days, dependent on the available infrastructure and personnel. Last, the diagnostic benefit decreases with growing experience of the surgeon. Thus, printing a 3D model of each patient receiving laryngotracheal surgery might not be feasible, and also not necessary.

In summary, a set of 3D models of typical and also exceptional cases can contribute to a deeper understanding of complex airway stenoses. 3D models should be considered an additional way to visualize a surgical problem in a comprehensive manner.

Conclusions

3D printed airway models are a tool which can increase the diagnostic accuracy of subglottic stenosis and improve surgical planning of a resection. The broad availability of 3D printing and the relatively easy access will foster the use of these models in training and in clinical practice.

References:

1. Tsai A et al. JTCVS Tech 2021;ahead of print.

2. Les AS et al. Laryngoscope 2019;129:1763-71.

3. Kamran A et al. JTCVS Tech 2021;8:160-9.

4. Schweiger T et al. J Thorac Cardiovasc Surg 2018;156:2019-21.

5. Leung G et al. S Int J Pediatr Otorhinolaryngol 2022;155:111083.

6. Hashimoto K et al. JTCVS Techniques 2022;online, ahead of print.

7. Schweiger T et al. J Thorac Cardiovasc Surg 2022;163:313-22 e3.

8. Hoetzenecker K et al. Ann Thorac Surg 2019;107:1860-5.

Open Surgical Approach to Tracheal Stenosis

Lauren Taylor, MD
Chief Resident, Cardiothoracic Surgery

John D Mitchell, MD
Davis Endowed Chair in Thoracic Surgery
Professor and Chief, General Thoracic Surgery
University of Colorado

Introduction:

Tracheal or laryngotracheal stenosis may result from a broad spectrum of underlying etiologies including gastroesophageal reflux disease, systemic disorders such as scleroderma or sarcoid, infection, malignancy, or radiation injury. At times, the cause of the stenosis cannot be specified, and is termed idiopathic. However, internal trauma due to endotracheal intubation or tracheostomy is the most common cause of acquired stenosis.[1] The dramatic rise in mechanical ventilation due to the COVID-19 pandemic further solidifies this as a causative frontrunner.[2] While endoscopic interventions are often first-line therapy for symptom palliation, recurrence is common. Surgical resection and airway reconstruction offers definitive treatment with high rates of success.[3,4]

Patient Evaluation and Indications:

Patients with acquired tracheal stenosis typically present with a history of dyspnea exacerbated by exertion which may progress to wheezing or stridor in the setting of advanced disease. Symptoms severe enough to rise to medical attention typically occur when stenosis has reached at least 50% of the airway diameter and initial misdiagnosis with more common respiratory ailments is common.[5,6] Workup includes pulmonary function tests, serologic evaluation for antineutrophil cytoplasmic antibodies, and computerized tomography (CT) of the neck and chest. Dynamic CT may facilitate identification of tracheomalacia which may accompany tracheal stenosis in select patients. Grading systems include the Myer-Cotton system which is based on stenotic severity and the McCaffrey system which categorizes based on location and length of stenosis.[7,8]

Bronchoscopy is the gold standard diagnostic technique and remains essential to evaluating surgical candidacy. While rigid bronchoscopy has been promoted in patients with more severe symptoms,[1] we have found flexible bronchoscopy to be sufficient in the majority of patients. We typically perform this with the patient under general anesthesia but without paralytics in order to evaluate vocal cord function and the degree of airway collapse due to associated tracheomalacia. The procedure is performed with a laryngeal mask airway in place and temporary removal of the tracheostomy tube, if present, to allow thorough evaluation of the airway. Key components of the exam include assessment of: (1) type of lesion, (2) location of stenosis including involvement of the cricoid cartilage, (3) length of stenosis, (4) involvement of other structures, notably the proximal larynx, (5) glottic aperture, (6) recurrent laryngeal nerve function, and (7) length of normal trachea. In the setting of subglottic stenosis, assessment of the subglottic aperture is critical to successful surgical resection; this region must be of sufficient diameter and free of inflammation or other mucosal abnormality. (Figure 1)

There is no age threshold that precludes a patient from surgical consideration and the procedure is generally well tolerated even in older, frail patients. However, there are several pre-existing conditions that warrant careful consideration during preoperative evaluation. While patients with borderline pulmonary function often tolerate tracheal resection, surgery should be avoided in those who are likely to require postoperative mechanical ventilatory support, or patients with conditions that put them at high risk of requiring intubation postoperatively, such as individuals with poorly controlled myasthenia gravis prone to respiratory decompensation. In addition, patients with pre-existing neurologic dysfunction pose a particular challenge to successful surgery, as patient cooperation with airway clearance and tolerance of the guardian stitch to avoid excessive head movement postoperatively is critical. Similarly, any suggestion of aspiration needs to be thoroughly investigated preoperatively. These patients may require tracheostomy permanently or until neurologic function improves. Finally, modifiable risk factors including obesity and steroid use should be rectified prior to surgery.

Procedural Considerations:

There is rarely an indication for emergent tracheal resection; surgery in this setting may be fraught with complications. Patients in extremis are often better served with tracheostomy or endoscopic intervention such as dilation to secure the airway with plans for formal surgical resection and reconstruction after their condition has temporized. Similarly, it is prudent to delay resection in the setting of active infection near the operative field as well as excessive local inflammation due to recent tracheostomy or dilation.

A key to successful tracheal resection and primary anastomosis is determination of how much trachea may be removed safely. Over the years, investigations performed in animals and human cadavers have measured anastomotic tension with various lengths of resection in an attempt to answer this question.[9-12] Unfortunately at present no reliable means of intraoperative measurement of anastomotic tension exists and this technique is not routinely used in practice. While precise limits of tracheal resection remain elusive, about 50% of the adult trachea may be safely removed in most cases. It is generally accepted that permissible lengths vary based on patient age, body habitus, and history of prior neck or chest surgery that may limit tracheal mobility due to scarring. For a stenosis of the proximal airway, neck flexion as well as surgical release maneuvers such as mobilization of the pre-tracheal plane or suprahyoid laryngeal release have been shown to decrease anastomotic tension and allow surgeons to push the boundaries of resection; for distal airway stenosis, a hilar release can afford similar advantages.

Resection of subglottic stenosis is typically performed through a collar incision, with excision of the stoma site if a tracheostomy was present. Additional upper neck incision, sternotomy, or thoracotomy may be required in some instances depending on location of the tracheal lesion and need for release maneuvers. Neck extension is achieved through careful patient positioning with a pillow between the scapulae and is critical to ensure adequate exposure of the operative field. In addition, bronchoscopy may be used intraoperatively to localize the lesion at the time of tracheal transection.

Subglottic stenosis poses particular surgical challenges due to the relatively narrow caliber of the laryngotracheal region and particular care must be taken to preserve the vocal cords when cricoid resection is necessary. The anastomosis is performed in an end-to-end fashion using interrupted absorbable sutures. We commonly use a strap muscle to buttress the anastomosis and prevent fistula development. At the time of primary anastomosis, the patient's neck is moved to a flexed position to minimize tension. We typically do not place T-tubes but favor placement of a guardian stitch prior to extubation to limit neck mobility during the first week after surgery.

An experienced anesthesia team is essential and constant communication between surgeon and anesthesiologist is needed to ensure surgical success. A variety of airway management strategies during tracheal resection have been described. While surgical cross-field intubation and jet ventilation are the most well-established, newer techniques have been proposed including use of supraglottic airways, regional anesthesia, and extracorporeal support.[13,14] We favor endotracheal intubation after induction of general anesthesia with a small caliber endotracheal tube as needed to accommodate the degree of stenosis. After tracheal transection, the surgeon places an armored endotracheal tube distally in the airway and cross-field ventilation is used until the anastomosis is complete.

Postoperative Care and Surveillance:

The majority of patients are extubated in the operating room at the conclusion of surgery. If ongoing mechanical ventilation is necessary, it is essential to ensure that the cuff of the endotracheal tube is positioned distal to the anastomosis with minimal inflation. Decadron may be indicated for some patients if significant laryngeal edema is present. All of our patients are monitored in the intensive care unit and kept nil per os for the first 24-48 hours postoperatively until formal swallow evaluation is complete. We keep the guardian stitch in place until postoperative day 7 at which time bronchoscopy is performed. If the anastomosis is healing appropriately, the stitch is removed along with surgical drains and the patient is discharged home.

We routinely follow patients with serial bronchoscopic evaluations after hospital discharge. (Figure 2) This facilitates early detection of anastomotic complications and allows for interventions such as debridement of granulation tissue or dilation of anastomotic strictures. In the setting of tracheal resection for tumor, bronchoscopy also serves the added role as surveillance of cancer recurrence.

Surgical Complications and Outcomes:

Complications of tracheal resection and reconstruction have been minimized with advances in surgical technique. However, a variety of anastomotic and other complications may still arise. Formation of granulation tissue at the anastomosis is one of the more common complications (although less frequent with the use of absorbable suture) and may be addressed by vigilant bronchoscopic follow-up postoperatively. Excess anastomotic tension or impaired tracheal blood supply due to over-dissection may lead to necrosis, separation or stricture that may be rectified with endoscopic techniques or in some instances require re-resection. Hemorrhage due to innominate artery erosion may occur if care is not taken to ensure that the artery does not rest in direct contact with the anastomotic sutures. Similarly, vocal cord dysfunction and subsequent aspiration may result from an error in surgical technique and failure to protect the nerves during tracheal dissection. A rare but debilitating complication to consider during patient positioning is quadriplegia due to extreme cervical flexion or extension.

Despite known complications, contemporary literature reports improved surgical outcomes. A recent retrospective analysis of 228 consecutive laryngotracheal resections performed over the last decade demonstrates 0% perioperative mortality rate. The overall complication rate was 9.6%; 7.8% are attributed to airway complications with the most common being restenosis. At a mean follow up of 65.5 months, definitive treatment success was achieved in 98.7% of patients.[3] Similar success was reported by Wang and colleagues in 2015 with 96% of patients who underwent surgical resection for idiopathic subglottic stenosis achieving good to excellent postoperative results.[15] Findings reported by

D'Andrilli et al. echo these results with definitive good or excellent results in 94.5% of their cohort and a complication rate of 9.2%.[4]

Conclusions:

Surgical resection and reconstruction offers definitive treatment of tracheal stenosis with recent literature demonstrating encouraging trends in improved postoperative outcomes. Surgical treatment of this disease is likely to play an increasingly prominent role due to the prevalence of mechanical ventilation attributed to the COVID-19 pandemic. Adherence to meticulous surgical techniques and the participation of experienced teams in high-volume centers is important to ensure surgical success, particularly in the setting of subglottic stenosis.

References:

1. **Aravena C et al. J Thorac Dis. 2020;12(3):1100-1111. doi:10.21037/jtd.2019.11.43**
2. **Piazza C et al. Eur Arch Otorhinolaryngol. 2021;278(1):1-7. doi:10.1007/s00405-020-06112-6**
3. **Maurizi G et al. J Thorac Cardiovasc Surg. 2021 Mar;161(3):845-852. doi: 10.1016/j.jtcvs.2020.12.023. Epub 2020 Dec 14. PMID: 33451851.**
4. **D'Andrilli A et al. Eur J Cardiothorac Surg. 2016 Jul;50(1):105-9. doi: 10.1093/ejcts/ezv471. Epub 2016 Jan 19. PMID: 26792926**
5. **Maldonado F et al. Orphan Tracheopathies. In: Cottin V, Cordier JF, Richeldi L, editors. Orphan Lung Diseases. London: Springer London, 73-89.**
6. **Costantino CL et al. J Thorac Dis 2016;8:S204-9.**
7. **McCaffrey TV. Laryngoscope 1992;102:1335-40. 10.1288/00005537-199212000-00004**
8. **Myer CM et al. Ann Otol Rhinol Laryngol 1994;103:319-23. 10.1177/000348949410300410**
9. **Cantrell JR et al. J Thorac Cardiovasc Surg 1961;42:589–98.**
10. **Kotake Y et al. J Thorac Cardiovasc Surg 1976;71:600–4.**
11. **Michelson E et al. J Thorac Cardiovasc Surg 1961;41:748–59.**
12. **Grillo HC et al. J Thorac Cardiovasc Surg 1964;48:741–9.**
13. **Schieren M et al. J Cardiothorac Vasc Anesth. 2017 Aug;31(4):1351-1358. doi: 10.1053/j.jvca.2017.03.020. Epub 2017 Mar 24. PMID: 28800992.**
14. **Schieren M et al. Anesth Analg. 2018 Apr;126(4):1257-1261. doi: 10.1213/ANE.0000000000002753. PMID: 29293182.**
15. **Wang H et al. Ann Thorac Surg.2015;100:1804-11.**

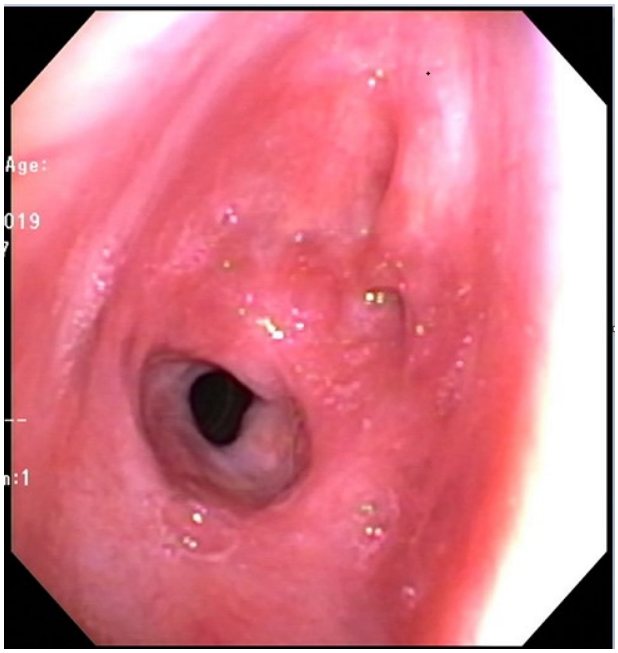

Figure 1: Preoperative flexible bronchoscopy demonstrates significant subglottic stenosis. This patient was deemed to be a suitable operative candidate and underwent laryngotracheal resection.

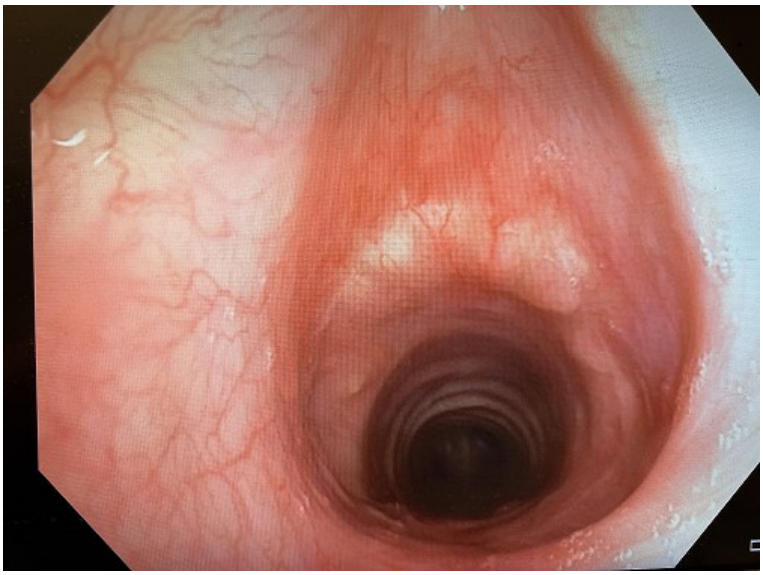

Figure 2: Postoperative surveillance bronchoscopy in the patient with subglottic stenosis who underwent laryngotracheal resection demonstrates that the anastomosis is healing well without evidence of stricture.

PARAGUAY PROJECT

In November 2021 the World Bronchology Foundation (WBF) received, from Paraguay, a request for help to treat patients with post-intubation tracheal stenosis due to COVID. Concretely, Dr Domingo Regalado Pérez asked the Foundation for a rigid bronchoscope and for providing training to deal with this unforeseen difficulty of the COVID pandemic. Dr Domingo Regalado Pérez is the head of the Pneumology Service of the General Luque Hospital, which belongs to the Ministry of Public Health in Paraguay, and is also a member of the WBF Board. The aim of the Project was to bring a rigid bronchoscope with optics, light source, camera and forceps and to conduct a course-workshop on the use of the rigid bronchoscope and thoracic ultrasound. For this project, support and funding was sought from the Asociación Española de Endoscopia Respiratoria y Neumología Intervencionista (AEER), the Sociedad Española de Neumología y Cirugía Torácica (SEPAR) and help from the commercial companies Ibersurgical and Suministros Hospitalarios. For this project, the AEER, and SEPAR gave financial support, while the companies Ibersurgical and Suministros Hospitaraios gave material". The culmination of the project consisted in a week-long trip to Paraguay which took place the last week of March 2022 where three professionals were awarded to take part in the trip, Dr. Javier Flandes and Dr. Enrique Cases by AEER and the nurse Susana Alvarez by SEPAR. Prior to the trip, all the expected material was obtained, as well as various prostheses and different endoscopic material, so that the budget reached for this project was around 25,000 €.

Once in Paraguay, the first day of the course-workshop was held at the Hospital Central del IPS-Asunción, where a series of lectures on rigid bronchoscopy and thoracic ultrasound were given. It is worth mentioning the presentation on bronchoscope reprocessing given by nurse Susana Alvarez, as the lecture aroused a lot of interest among the attending doctors. In addition, during the second they of the course, nurse Susana had the opportunity to collaborate with the nurses working at above mentioned hospital, as well as with nurses working in other hospitals from Auncion and Luque. Not only she was able to collaborate but also to conduct presentations and workshops on reprocessing, sedation and the handling of endoscopic samples.

The following days of the Course-Workshop were held at the Hospital General of Luque. Luque is a city of Paraguay located in the Central Department near to Asunción which is the current capita of Paraguay. In this hospital were addressed topics related to the rigid bronchoscopy and thoracic ultrasound as well as other issues such as the diagnostic and therapeutic possibilities of the cryoprobe, thermoplasty, the endoscopic diagnostic possibilities of the pulmonary nodule or pleural pathology were developed. In this hospital, we had the possibility to participate in the treatment of two patients suffering from tracheal stenosis. The patients were treated with the new rigid bronchoscope and were placed a Dumon prosthesis and a Leufen prosthesis donated by Suministros Hospitalarios. Thanks to the optical and camera equipment donated by Ibersurgical, the two interventions were visualised by the young pneumologists. Thoracic ultrasound scans were also performed in different departments of the hospital to familiarise the pneumologists with the different pathologies and some specific diagnoses were made, such as a diaphragmatic paralysis in a ventilated patient who was difficult to wean.

The course was attended by around twenty-five young pulmonologists from different cities of Paraguay who showed their enthusiasm for interventional pneumology and their eagerness for training in this field. We would like to thank the Sociedad Paraguaya de Neumología and its president Dr. José Oviedo for their warm welcome and for the logistical and technical support we were given, without which this project would not have been possible. We would also like to thank the pneumologists Dr Domingo Pérez, soul of the Project in Paraguay, Dr Gilberto Chaparro whose experience in interventional bronchoscopy we consider fundamental for the further development of this Project, the young pneumologists who participated t in the course and the members of the Pneumology Service of the General Hospital of Luque in whose hands lies the future of interventional pneumology in Paraguay, Dr Diego Medina, Dr Avid Aluan, Dr Silvio Benitez, Dr Liza Davalos, Dr Sergio Cárdenas, Dr Diego Aguayo and Dr Carlos Pallarolas.

In addition to this Project in Paraguay and the previous Projects developed with AEER and SEPAR Solidaria in Panama, El Salvador and Honduras in 2018, the WBF participated in the SEPAR Solidarity Project held in the Sahrawi Refugee Camps in Algiers. In this project, a GeneXpert was brought for the diagnosis of tuberculosis and which has been fundamental for the

Humanitarian News

diagnosis of COVID in this Camp. There is a project underway to bring a bronchoscope to the camp and to provide training to a digestive endoscopist to work in the refugee camp, because the camp does not have a pulmonologist and there are nearly 200,000 people living there with limited means and depending on external aid.

Best Image Contest

Best Image Contest 2022 (2 of 3)

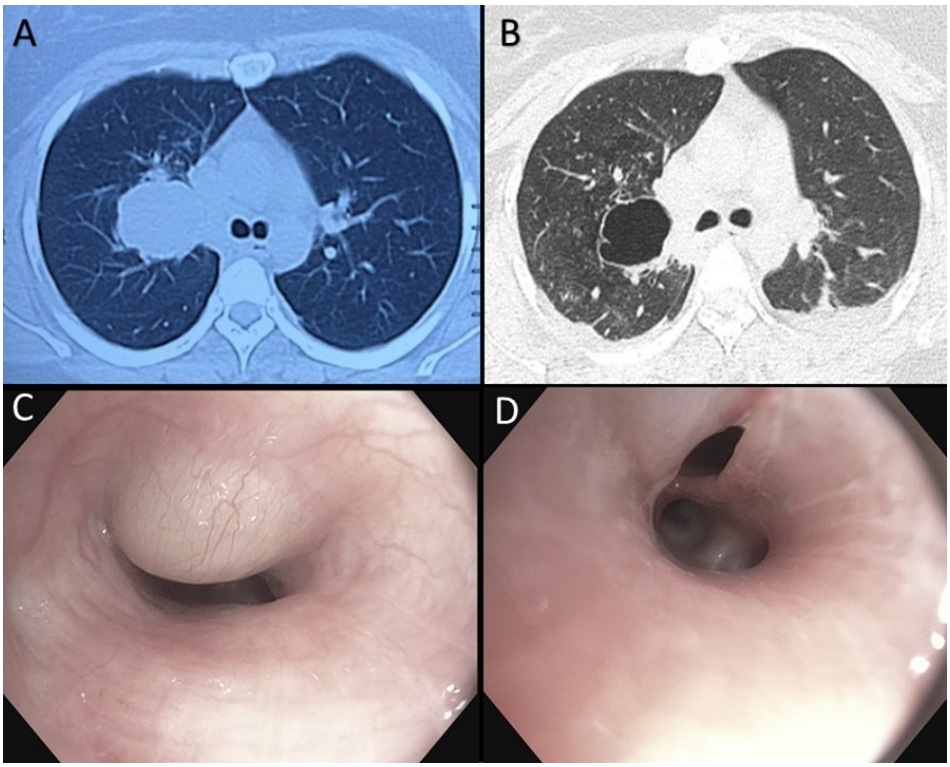

Description:

Spontanous rupture of Bronchogenic Cyst
A- Axial CT view of the bronchogenic cyst before rupture
B- Axial CT view of the bronchogenic cyst after rupture
C- Bronchoscopy view of intact bronchogenic cyst in the right upper lobe
D- Bronchoscopic view of ruptured bronchogenic cyst causing breach on the bronchial wall

Submitter:

Dr. Roshan Kumar

This image is the 1 of 3 selected among 100+ submissions to our Best Image Contest held in late 2021. Please stay tuned to the next Image Contest opening later this year. Find the above image and more at the WABIP Academy Image Library at https://www.WABIPacademy.com/imagelibrary

WABIP News

WCBIP 2022 Registration Discounts Ending Soon

Take advantage of registration discounts of up to 33% until July 15, 2022 for WCBIP Marseille 2022. If you register for "remote access" (virtual) first, you can upgrade to on-site access at any time, even at the venue. In which case, the price difference will be invoiced.

REGISTER NOW at https://www.wcbip.org/general#fees

WABIP Vice Chair Nominations

Nominations for the next WABIP Vice-chair are still open until July 1, 2022. If you would like to consider a colleague for the chance to be the next Vice-chair, you may nominate by downloading and completing the following form @ https://cdn.wabip.com/downloads/vice-chair/WABIP-Vice-Chair-Nomination-Form-2022.pdf

WCBIP 2026 Bids

As the above, the deadline for WCBIP bids applications is July 1, 2022. We cordially invite you to submit a bid for organizing our biennial congress which shall take place 4 years from now. Download and complete the following form to begin @ https://www.wabip.com/news/544-wcbip2026bids2

WABIP Awards

Celebrate and give recognition to your outstanding colleague in the IP community by nominating him or her for a WABIP Award. Nominations for the Killian Medal, the Dumon Award and the Lifetime Achievement Award are due by July 1, 2022. You may nominate yourself for the Becker Award upon submitting an abstract for WCBIP 2022. More details at https://www.wabip.com/awards

WABIP Board of Regents Meeting in Marseille

We are pleased to announce that the next BOR meeting will be held in Marseille on-site this October 6, 2022 at 1:00 pm CEST. For those who cannot attend on site, Regents may join via Zoom. This meeting will include elections for next WABIP Vice-chair and voting for WCBIP 2026 host site, as described above. General members: please be sure to contact your society representative (Regent) so that he/she may represent your vote.

Associate editor:

Dr. Ali Musani

Editor-in-Chief: Dr. Kazuhiro Yasufuku

Primary Business Address:

Kazuhiro Yasufuku, Editor-in-Chief WABIP Newsletter

c/o Judy McConnell

200 Elizabeth St, 9N-957

Toronto, ON M5G 2C4 Canada

E-mail: newsletter@wabip.com

Associate editor:

Dr. Septimiu Murgu

Research

The Mantra of Medicine

Multidisciplinary Approach and Personalized Therapy

Ali I. Musani MD, FCCP

University of Colorado School of Medicine,

Denver

Idiopathic subglottic stenosis (ISGS) is a rare (1:400,000), recurrent, fibroinflammatory disease that results in debilitating and life-threatening airway obstruction. While ISGS is a rare condition, it is well-known to interventional pulmonologists, laryngologists, and thoracic surgeons.

Causes of ISGS include congenital, trauma such as intubation or tracheostomy, inflammatory conditions, and idiopathic diseases. This disease can lead to debilitating symptoms such as dyspnea, cough, hoarseness, stridor, and sleep apnea. Often the management options are limited, invasive, or suboptimal, with recurrences requiring repeated interventions. In many cases, quality of life is severely affected. Unfortunately, due to the young age of patients in most of these cases, the impact of this disease is felt even more.

As interventional pulmonologists, we often utilize rigid bronchoscopic dilations, endobronchial ablative therapies, injections of antifibrotic agents such as steroid and mitomycin, and airway stenting. Our colleagues in ENT usually perform balloon dilations and CO2 laser ablation with or without antifibrotic injection, while thoracic surgeons perform cricotracheal resection (CTR) and end to end anastomosis of the trachea in select cases when feasible. The treatment approaches are often institution and provider-dependent. As we all have been taught in our training, rare and complex diseases like ISGS should have a multidisciplinary approach to provide personalized therapy at expert centers. This offers the best chance to give patients a long-term and definitive treatment.

A large study (1) recently tried to answer the quintessential question of the best treatment strategy for ISGS. The study prospectively compared the outcomes of the three most common approaches for managing ISGS. It recruited ISGS patients with or without previous treatment from multiple centers across the United States in a prospective manner. The study's primary endpoint was the time between the initial and second procedures. Secondary endpoints of the study included quality of life, voice handicap, eating assessment, functional health, and postoperative complications. Eight hundred and ten patients were enrolled in the study. Initial surgical procedures were endobronchial dilation (n = 603; 74.4%), endobronchial

resection and medical therapy (n = 121; 14.9%), and surgical therapy with CTR (n = 86; 10.6%). Overall, 22.8% of patients had a recurrent surgical procedure during the 3-year study. However, the recurrence rates differed in three treatment groups, CTR, 1.2%; endobronchial with medical therapy, 12.4%; and endobronchial dilation, 28.0%. Among successfully treated patients without recurrence, those treated with CTR had the best quality of life, the worst voice symptoms, and the most significant perioperative risk. The most used therapeutic approach, endoscopic dilation, was associated with a higher recurrence rate than other procedures. In contrast, endoscopic resection with medical therapy (treatment of choice by the interventional pulmonologists) was associated with better disease control than endoscopic dilation and had a minimal association with vocal function.

This study substantiates the algorithmic approach of ISGS in a multidisciplinary fashion. In our practice, every ISGS patient is referred to thoracic surgery for CTR if feasible. Unfortunately, most patients do not qualify for CTR due to confounders, including stenosis too close to the vocal cords, long previous surgeries, and anatomical and medical issues. Our second line of treatment for ISGS is an interventional pulmonology comprehensive approach with endotracheal resection/debulking and dilation with rigid bronchoscopy and endotracheal steroid injections, with or without stent and ablative therapies such as laser or cautery. Stents and ablative therapies are uncommonly used nowadays. Our other adjuvant strategies include robust medical and behavioral control of gastroesophageal reflux disease, management of hiatal hernia if contributing to reflux, aggressive treatment of obesity, and workup and treatment of autoimmune diseases.

The answer to the question as to the best approach for these patients remains, "it depends"! It depends on the location of the stenosis, comorbidities, other confounding issues as mentioned above, and perhaps most importantly, the expertise of the treating institutions and physicians. Hence, the mantra of "multidisciplinary approach to offer personalized therapy." Furthermore, as mentioned earlier, the key is to refer these patients to the expert centers once the diagnosis is established and the initial treatment is provided to prevent acute respiratory compromise. This strategy has been proven to offer patients the best chance of meaningful recovery and the best quality of life.

Reference:

1. Gelbard et al. JAMA Otolaryngol Head Neck Surg. 2020 Jan 1;146(1):20-29.

WABIP ACADEMY- WEBCASTS

The WABIP has started a new education project recently: *THE WABIP ACADEMY.* The WABIP Academy will provide free online webcasts with new and hot topics that will interest pulmonologists and interventionalists.

Current webcast topic: **Tissue acquisition for biomarker directed therapy of NSCLC**

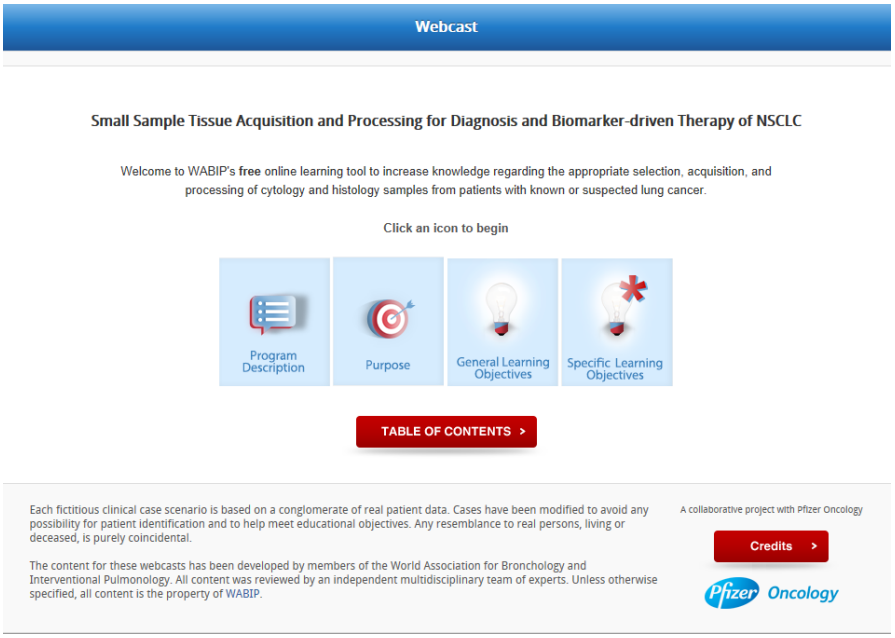

You can reach these webcasts by using this link: http://www.wabipacademy.com/webcast/

Links

www.bronchology.com	Home of the Journal of Bronchology
www.bronchoscopy.org	International educational website for bronchoscopy training with u-tube and facebook interfaces, numerous teachiing videos, and step by step testing and assess ment tools
www.aabronchology.org	American Association for Bronchology and I nterventional Pulmonology (AABIP)
www.eabip.org	European Association for Bronchology and Interventional Pulmonology
www.chestnet.org	Interventional Chest/Diagnostic Procedures (IC/DP) NetWork
www.thoracic.org	American Thoracic Society
www.ctsnet.org	The leading online resource of educational and scientific research information for cardiothoracic surgeons.
www.jrs.or.jp	The Japanese Respirology Society
sites.google.com/site/asendoscopiarespiratoria/	Asociación Sudamericana de Endoscopía Respiratoria

OLYMPUS

Enhanced access and control to allow staging and diagnosis

Better access to difficult-to-reach lymph node stations
The powerful angulation supports smoother insertion to the upper/lower lobe bronchi and allows more of a bend in the scope when an EndoTherapy device is inserted in the working channel.

Easier intubation and orientation BF
The decreased forward oblique angle allows for easier EBUS scope insertion.

Enhanced image quality
The endoscopic image of the BF-UC190F/BF-UC290F has higher resolution than BF-UC180F/BF-UC260FW. This enhances visualization with a clearer image.

EVIS EUS ULTRASOUND BRONCHOFIBERVIDEOSCOPE

BF-UC190F/BF-UC290F

*BF-UC190F and/or BF-UC290F are not available in some areas.

EVIS EUS

OLYMPUS MEDICAL SYSTEMS CORP.
2951 Ishikawa-machi, Hachioji-shi, Tokyo 192-8507, Japan

www.olympusprofed.com

LCR43411V01

Single-Use Bronchoscopy Redefined.

Boston Scientific
Advancing science for life™

EXALT™ Model B
Single-Use Bronchoscope

Boston Scientific has designed its single-use bronchoscope to bring a new level of performance to the intensive care setting. This new device was developed to provide high-quality images and familiar scope maneuverability, yet it is the innovative design of the working channel that enables superior suction — making this single-use bronchoscope different.[1] *

1. Model B delivers superior suction power in water across all scopes of the same size as compared to tested commercially available single-use and reusable bronchoscopes.

* Data on file – Boston Scientific benchtop study testing 15 units each of 9 single-use scope models, and 1 each of 4 reusable scope models (each tested 15 times with a new suction valve) under constant pressure for 30 seconds testing two different viscosity substances. The volume of substance suctioned via the bronchoscope was the primary outcome. One-way ANOVA was used to test statistical significance between scopes with an alpha of 0.05. Bench test results may not necessarily be indicative of clinical performance.

Caution: U.S. Federal law restricts this device to sale by or on the order of a physician.

Boston Scientific is a Global Company. Please note that model numbers, indications, contraindications, warnings and specifications may differ depending on geographic region. Not all information displayed in this brochure may be licensed in accordance with Canadian law. Please contact your Boston Scientific representative for local labeling, product specifications and licensed model numbers.

L27CA 389 0420