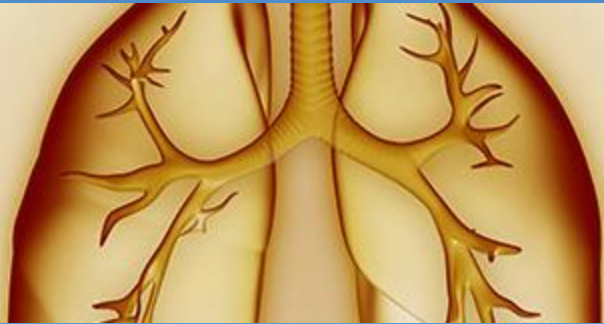



Rare Lung, Pleura, and Airway Disorders



Infections Causing Central Airway Obstruction

Sevak Keshishyan MD,
Kassem Harris MD, FCCP

Co-Chair: WABIP Rare Lung, Pleura & Airway Disorders





Infections Causing Central Airway Obstruction: A rare manifestation of a common disease



Fungal infections

Aspergillus spp.

Histoplasma spp.

Fusarium spp.

Coccidioides immitis

Penicillium spp.

Candida spp.

Mucorales spp.

Pseudallescheria boydii

Cryptococcus spp.

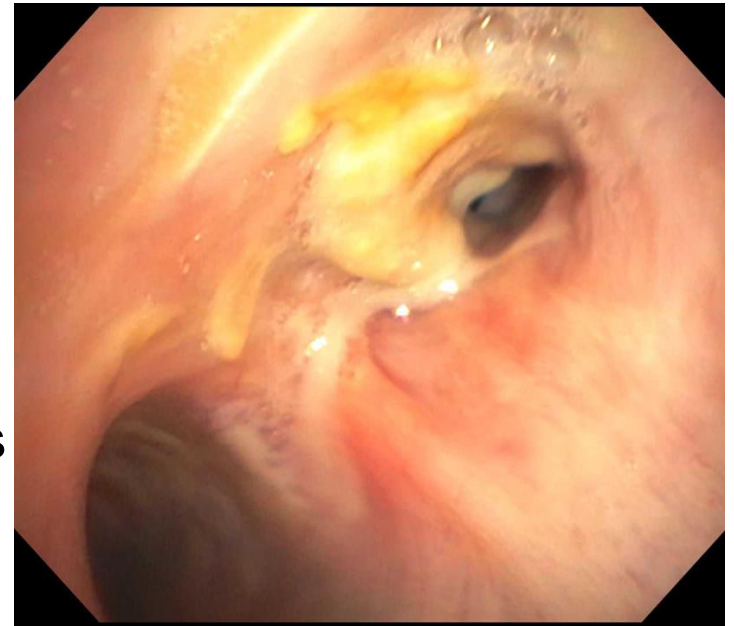


Aspergillosis

Most commonly reported fungal pathogen
More common in immunocompromised
patients

Bronchoscopic appearance:

- Wall edema
- Necrotizing pseudomembranous lesions
- Ulcerative lesions
- Whitish or yellowish plaques
- Endoluminal masses and vegetations



Endobronchial aspergillosis causing RMS
airway obstruction. Courtesy of Dr. Harris



Bronchoscopic treatment options:

- Rigid bronchoscopy
- Forceps removal of aspergilloma
- Aspiration of mass
- Bronchoscopic debridement
- Partial resection of the lesions
- Dilation
- Removal of pseudomembranes
- Silicone stent placement
- Electrocautery and cryotherapy
- Laser



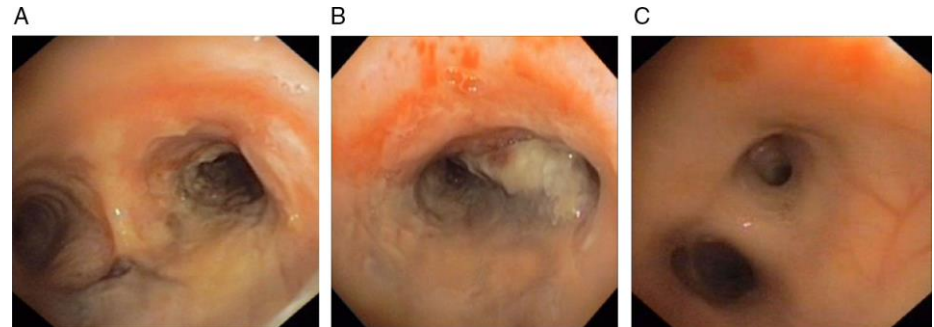
Mucormycosis

Common in diabetic patients with ketoacidosis

Hallmark of clinical presentation is hemoptysis (due to angioinvasive nature of disease)

Bronchoscopic appearance:

- Mucoid plugs yellowish or whitish in color
- Endobronchial mass or polypoid lesion
- White cheese-like mass
- Plaques and area of necrosis



Bronchoscopic image showing (A) main carina with mucosal oedema in the right main bronchus, (B) mucosal oedema and whitish plaques in the right main bronchus and (C) the left main bronchus which is apparently normal.



Mucormycosis

Bronchoscopic treatment:

- Rigid bronchoscopy
- Removal of the lesion via bronchoscopy
- Forceps debridement and removal of mucoid plug
- Forceps balloon dilation
- Stent placement
- Endobronchial laser therapy for obstruction
- Cryotherapy
- Argon Plasma Coagulation



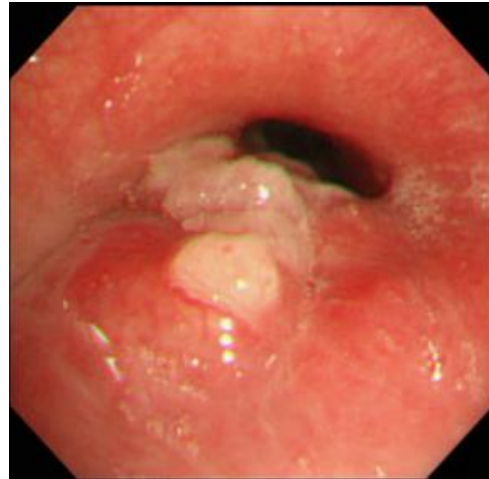Cryptococcosis

Common in immunocompromised patients, especially with AIDS

Usual presentation is with mediastinal and hilar lymphadenopathy, fever, cough, dyspnea and sometimes hemoptysis

Bronchoscopic appearance:

- Whitish or yellowish mass
- Mucous plug
- Red or white thrush like plaques
- Mucosal granularity
- White granulation tissue
- Ulcerated elevated lesion and polypoid mass



Bronchoscopic findings showed aggregated white nodes in the compressively stenosed left main bronchus

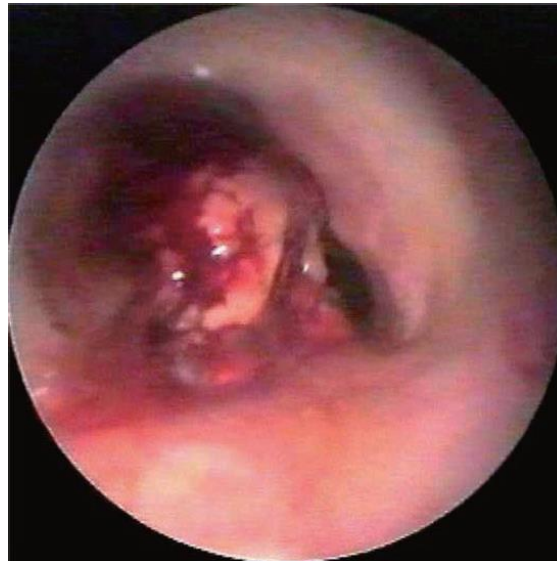Respirol Case Rep.
2014;2(3):108-10.



Cryptococcosis

Bronchoscopic treatment options:

- Rigid bronchoscopy with electrocautery and snare resection
- Removal of the neoplasm with high frequency electric ablation
- Argon Plasma Coagulation
- Stent placement
- Endobronchial laser resection



Exophytic mass arising from
the posterior tracheal wall
just beneath the vocal cords

Intern Med.
2013;52(11):1279.



Fusarium

Resembles aspergillus

Causes disseminated disease especially in neutropenic patients

Bronchoscopic appearance:

- large whitish cauliflower necrotic lesion - mycetoma

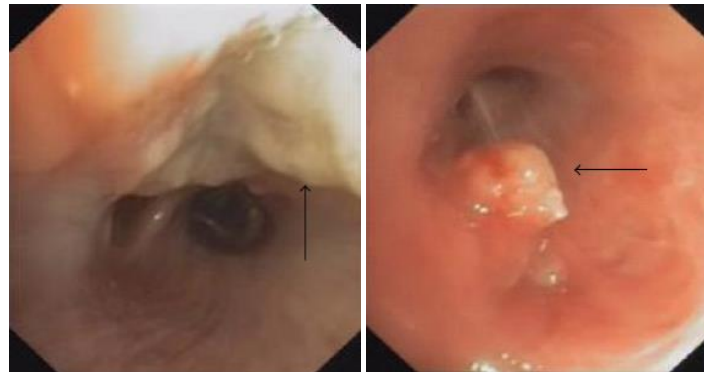
Bronchoscopic treatment:

- Removal of mycetoma with cryotherapy probe



Bacterial infections

- NTM spp. (*M. avium* complex , *M. kansasii*)
- *Actinomyces* spp.
- *Nocardia* spp.
- *Peptostreptococcus* spp.
- *Klebsiella* spp. (*K. rhinoscleromatis*, *K. pneumoniae*)
- *Staphylococcus aureus* - MRSA
- *Chlamydia psittaci*
- *Corynebacterium* spp.
- *Streptococcus pyogenes*
- *Pseudomonas aeruginosa*
- Bacillary angiomatosis
- *Rhodococcus equi*



Bronchoscopic images:
the arrows are pointing to
different views of
nocardial white friable
lesions (a) and mass (b)
in the right
lower lobe.

Case Rep Pulmonol.
2015;2015:970548



Actinomyces

Well described association with broncholiths and foreign bodies

Bronchoscopic appearance:

- White – yellow exophytic mass
- Endobronchial mass
- Large broncholith conglomerate
- Circumferential ulcerative lesions

Bronchoscopic treatment options:

- Endobronchial laser assisted extraction of broncholiths
- Rigid bronchoscopic debridement
- Y shaped stent placement
- Bronchoscopic removal of occluding mass
- Bronchoscopic removal of broncholiths using forceps

Clinical infectious diseases. 1996;22(6):1126-7
CHEST Journal. 2016;150(4_S):774A-A
Respir Care. 2014;59(3):e27-30
Rev Mal Respir. 2015;32(5):524-9

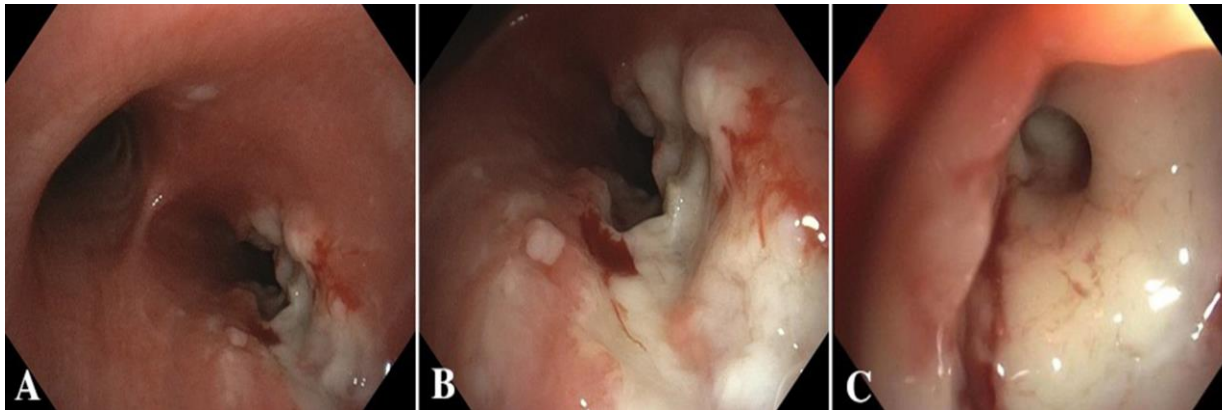


Mycobacterial infections

Can presents as part of immune reconstitution inflammatory syndrome as well as being part of disseminated infection, but also described in immunocompetent hosts

Bronchoscopic appearance:

- Polypoid lesions and white – yellow irregular mucosal lesions
- Endobronchial mass and multiple nodular lesions
- Ulcerative lesions with bronchial strictures
- Caseating endobronchial lesion



Bronchoscopic examination demonstrates area of cheese-like material and non-obstructing ulcerative lesion proximal to the entrance of the right main stem bronchus (A and B) with severe narrowing of the right upper lobe bronchus (C).

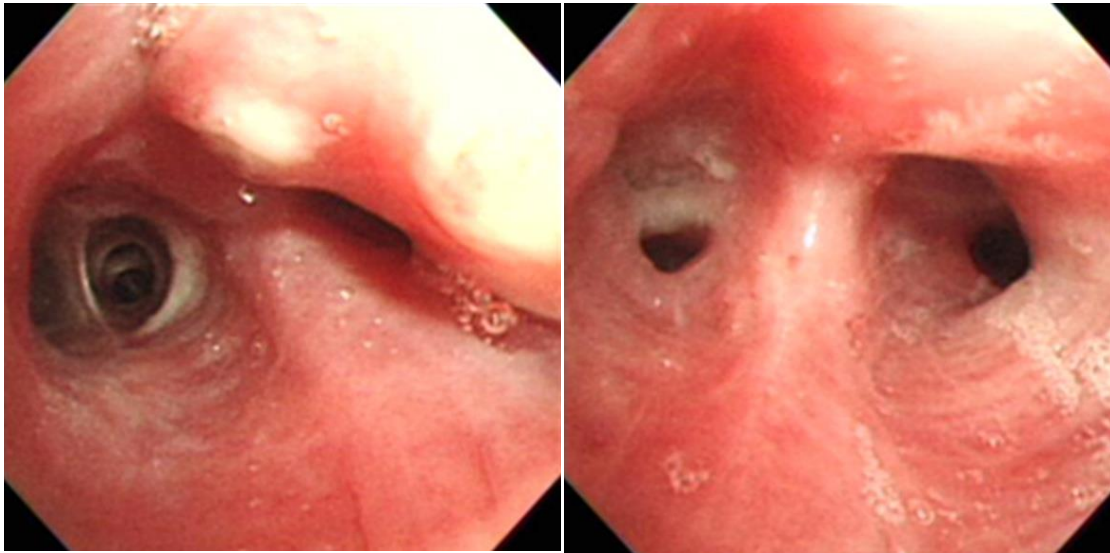
Courtesy of Harris and Alraiyes.



Mycobacterial infections

Bronchoscopic treatment options:

- Laser resection
- Balloon bronchoplasty
- Debulking bronchoscopy with cryotherapy



Bronchoscopic findings show elevated nodular lesions with central whitish necrosis at apical segment of the right upper lobe and luminal narrowing at the apical part of apicoposterior segment of the left upper lobe.

Tuberc Respir Dis 2013;75:157-160



Corynebacterium

Only few cases reported

Bronchoscopic presentation:

- Mild airway erythema
- Circumferential ulcerations
- Pseudomembranous plaque like lesions
- Severe obstruction of trachea

Bronchoscopic treatment options:

- Mechanical debridement
- Rigid bronchoscopy
- Dilatation with rigid bronchoscopy
- Removal of membranes from subglottic area by rigid bronchoscopy

Respiratory care. 2014;59(1):e5-e8.
Review of Infectious Diseases. 1991;13(1):73-6



Rhinoscleroma (Klebsiella rhinoscleromatis)

Rare chronic granulomatous infection mostly in endemic areas like Middle East, Mexico, Central America.

Bronchoscopic appearance:

- Diffuse polypoid lesions
- Subglottic tracheal tumor – like mass
- Mucosal hypertrophy

Bronchoscopic treatment options:

- CO2 laser endoscopic therapy for obstruction
- Endoscopic resection

The Journal of Laryngology & Otology. 1994;108(06):484-5
Canadian respiratory journal. 2005;12(1):43-5
Eur Ann Otorhinolaryngol Head Neck Dis. 2016;133(1):51-3



Methicillin Resistant Staphylococcus Aureus

Isolated endobronchial disease involving only major airways rarely reported

Bronchoscopic appearance:

- Hemorrhagic mucosal lesions
- White lesions with purulent exudates
- Mass of granulation tissue

Bronchoscopic treatment options:

- Granulation tissue removal by rigid bronchoscopy
- Placement of silicone stent



Pseudomonas aeruginosa

Bronchoscopic appearance:

- Fibroepithelial polyps
- Mass of granulation tissue

Bronchoscopic treatment:

- Granulation tissue removal by rigid bronchoscopy
- Argon plasma coagulation



Viral infections

- Varicella Zoster Virus (VZV)
- Cytomegalovirus (CMV)
- Herpes Simplex Virus (HSV) 1 and 2
- Influenza virus type A and B

Am Rev Respir Dis. 1990;142(4):884-6

Histopathology. 1993;22(3):265-70

J Clin Virol. 2013;56(4):360-4

American College of Chest Physicians. 2016;Annual meeting 2016:455 A.



Cytomegalovirus

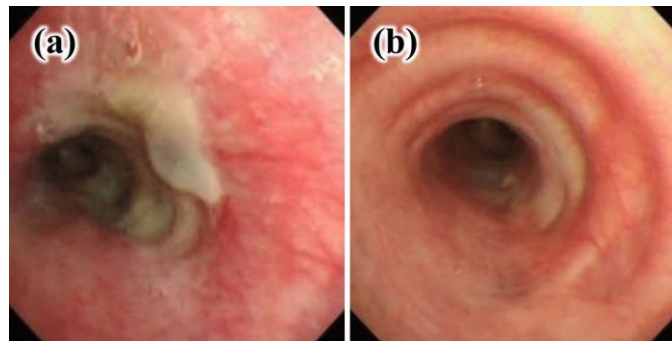
Most common virus causing pulmonary infection after lung transplantation and in AIDS patients

Bronchoscopic appearance:

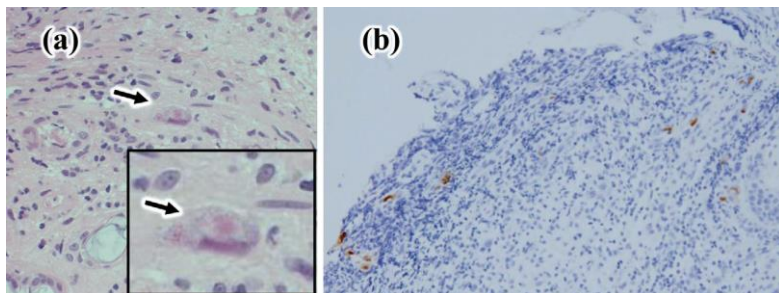
- Endobronchial polypoid lesions
- Exophytic mass
- Mucosal edema with ulcerations
- Granulation tissue at the site of stent

Bronchoscopic treatment options:

- Rigid bronchoscopy
- Bronchoscopic polyp removal
- Placement of new stent



(a) Bronchoscopy performed before treatment showed mucosal edema, flaring and ulceration with thick exudates in the left main bronchus. (b) Bronchoscopy performed after ganciclovir treatment revealed that the ulcerated lesion in the left main bronchus was replaced with a normal mucosa while only demonstrating slight scarring. *Intern Med.* 2012;51(20):2933-6



(a) Hematoxylin and Eosin staining of the biopsy specimens from the ulcerated lesion in left main bronchus (magnification: $\times 400$). The black arrow indicates a cytomegalovirus inclusion body. (b) Immunohistochemical staining of the biopsy specimens (magnification: $\times 100$). A number of cytomegalovirus-positive cells were detected.

Intern Med. 2012;51(20):2933-6



Herpes simplex virus

Bronchoscopic appearance:

- Fungating and endobronchial masses
- Polypoid lesions
- Mucosal irregularities and ulcerations causing airway stenosis
- Necrotic and vesicular blistering lesions

Bronchoscopic treatment options:

- Balloon dilation
- Bare metal stent

Eur Respir J. 2005;25(6):1117-20
Multidisciplinary respiratory medicine. 2013;8(1):1
Am Thoracic Soc; 2015. p. A5643-A.



Parasitic infections

- Strongyloides stercoralis
- Leech infestation
- Lophomonas blattarum
- Leishmaniasis

Arch Bronconeumol. 2003;39(11):524-6
J Thorac Dis. 2014;6(6):E73-6
Case reports in medicine. 2011;2011



Leech infestation

Extremely rare and there are only few isolated case reports

Bronchoscopic appearance:

- Brown worm-like moving foreign body 2 cm below the glottis surrounded with granulation tissue

Bronchoscopic treatment:

- Rigid bronchoscopy and forceps extraction



Conclusions

- Infections causing central airway obstruction are rare.
- In addition to medical treatment, bronchoscopic intervention for rapid symptomatic relieve or treatment of obstruction have been successfully performed.
- Bronchoscopic interventional modalities are probably safe adjunct to the treatment of central airway obstructive infections. The data are limited to case reports and series.
-



Rare Lung, Pleura, and Airway Disorders



This presentation was prepared by
Sevak Keshishyan MD and Kassem Harris MD, FCCP
and reviewed for accuracy and content by members of the
WABIP Rare Lung, Pleura and Airway Disorders section

